



Biliary Tract Cancer

Recommendations from the society for diagnosis and therapy of
haematological and oncological diseases

Publisher

DGHO Deutsche Gesellschaft für Hämatologie und
Medizinische Onkologie e.V.
Bauhofstr. 12
D-10117 Berlin

Executive chairwoman: Prof. Dr. med. Claudia Baldus

Phone: +49 (0)30 27 87 60 89 - 0

info@dgho.de

www.dgho.de

Contact person

Prof. Dr. med. Bernhard Wörmann
Medical superintendent

Source

www.onkopedia-guidelines.info

The information of the DGHO Onkopedia Web Site is not intended or implied to be a substitute for professional medical advice or medical care. The advice of a medical professional should always be sought prior to commencing any form of medical treatment. To this end, all component information contained within the web site is done so for solely educational purposes. DGHO Deutsche Gesellschaft für Hämatologie und Onkologie and all of its staff, agents and members disclaim any and all warranties and representations with regards to the information contained on the DGHO Web Site. This includes any implied warranties and conditions that may be derived from the aforementioned web site information.

Table of contents

1 Summary	2
2 Basics	2
2.1 Definition and basic information	2
2.3 Epidemiology	2
2.4 Pathogenesis.....	2
2.4.1 Precancerous lesions	2
2.5 Risk factors	2
3 Prevention and early detection	2
3.1 Prevention.....	2
3.2 Early detection.....	2
4 Clinical characteristics	2
4.1 Symptoms.....	2
5 Diagnosis	2
5.2 Diagnostics	2
5.2.1 Initial diagnosis	2
5.3 Classification.....	2
5.3.1 Classification according to localization	2
5.3.1.1 Perihilar tumors / Klatskin tumors: Classification according to Bismuth-Corlette	2
5.3.1.2 Perihilar/Klatskin tumors: Jarnagin-Blumgart/MSK classification	2
5.3.2 Stages and staging/TNM	2
5.3.2.1 Intrahepatic bile duct carcinomas (C22.1)	2
5.3.2.2 Gallbladder and Ductus cysticus carcinomas (C23.0 and C24.0).....	2
5.3.2.3 Perihilar bile duct carcinomas (C24.0)	2
5.3.2.4 Distal extrahepatic bile duct carcinomas (C24.0)	2
5.3.2.5 Carcinoma of the Ampulla Vateri (C24.1).....	2
5.3.3 Histological subtypes	2
5.3.3.1 General aspects of biliary differentiated cholangiocarcinoma	2
5.3.3.2 Gallbladder carcinomas	2
5.3.3.3 Carcinomas of the extrahepatic bile ducts	2
5.3.3.4 Carcinomas of the intrahepatic bile ducts	2
5.3.3.5 Carcinomas of the Ampulla Vateri, papillary carcinomas.....	2
6 Therapy	2
6.1 Treatment structure	2
6.1.1 Stage I-III	2
6.1.1.1 Surgical resection in stages I to III	2
6.1.1.2 Adjuvant therapy	2

6.1.1.2.1 Adjuvant chemotherapy.....	2
6.1.1.2.2 Adjuvant radio- and radiochemotherapy	3
6.1.1.3 Neoadjuvant/preoperative therapy	3
6.1.2 Stage IV biliary tract cancer	3
6.1.2.1 Systemic tumor treatment - stage IV.....	3
6.1.2.1.1 First-line therapy.....	3
6.1.2.1.2 Second-line therapy.....	3
6.1.2.1.3 Third-line therapy	3
6.1.2.1.4 Targeted therapeutic approaches	3
6.1.2.1.4.1 FGFR2 gene fusions and rearrangements.....	3
6.1.2.1.4.2 IDH1 mutations.....	3
6.1.2.1.4.3 BRAF V600 mutations	3
6.1.2.1.4.4 HER2/neu - overexpression, - mutation, - amplification.....	3
6.1.2.1.4.5 Microsatellite instability (MSI-H/dMMR).....	3
6.1.2.1.4.6 NTRK alterations	3
6.2 Treatment modalities	3
6.2.1 Resection	3
6.2.1.1 Resection of the intrahepatic bile ducts and liver.....	3
6.2.1.2 Resection of the extrahepatic bile ducts and pancreatic head	3
6.2.1.3 Liver transplantation.....	3
6.2.1.4 Surgical resection of metastases	3
6.2.2 Radiotherapy	3
6.2.3 Interventional local therapy procedures	3
6.2.4 Systemic tumor treatment.....	3
6.2.4.1 Anticancer agents.....	3
6.2.4.1.1 Capecitabine.....	3
6.2.4.1.2 Cisplatin.....	3
6.2.4.1.3 Durvalumab	3
6.2.4.1.4 5-Fluorouracil.....	3
6.2.4.1.5 Futibatinib.....	3
6.2.4.1.6 Gemcitabine	3
6.2.4.1.7 Irinotecan.....	3
6.2.4.1.8 Ivosidenib	3
6.2.4.1.9 Oxaliplatin.....	3
6.2.4.1.10 Pembrolizumab	3
6.2.4.1.11 Pemigatinib.....	3
6.3 Special treatment settings.....	3
6.3.1 Carcinomas of the Ampulla Vateri.....	3
6.3.1.1 Nomenclature	3
6.3.1.2 Diagnostics in carcinomas of the Ampulla Vateri.....	3

6.3.1.3 Therapy of carcinoma of the Ampulla Vateri.....	3
6.3.2 Symptomatic cholestasis	4
7 Rehabilitation	4
8 Monitoring and follow-up	4
8.1 Monitoring for disease progression	4
8.2 Follow-up	4
9 References	4
15 Authors' Affiliations	4
16 Disclosure of Potential Conflicts of Interest	4

Biliary Tract Cancer

ICD-10: C22.1, C23, C24.-

Date of document: April 2024

Compliance rules:

- [Guideline](#)
- [Conflict of interests](#)

Authors: Marianne Sinn, Dirk Arnold, Markus Borner, Karel Caca, Irene Esposito, Thorsten Oliver Götze, Klaus Kraywinkel, Jens Ricke, Daniel Seehofer, Alexander Stein, Arndt Vogel, Henning Wege, Thomas Winder

1 Summary

This guideline deals with biliary tract cancer, previously "malignant biliary tumors". This term is used as a entity including carcinomas of the intrahepatic and extrahepatic (perihilar/Klatskin tumors and distal) bile ducts and the gallbladder. In the international nomenclature, biliary carcinomas are also summarized as cholangiocarcinomas (CCA).

Biliary tract cancer is rare and accounts for less than 2% of malignant tumors.

In localized stages, complete surgical resection is the treatment of choice. Here, 5-year survival rates are 20-50%, depending on the stage, the selection of patients and the resection result. In locally advanced stages, treatment should generally be multimodal, especially in the case of intrahepatic tumor localization.

In the case of technically inoperable tumor manifestations, or the presence of contraindications to surgery and in the metastatic stage, systemic therapy is indicated as the primary treatment modality. In addition to tumor-specific therapies, the treatment of tumor-related cholestasis is an essential component of multidisciplinary care and crucial for avoiding life-threatening complications (cholangiosepsis).

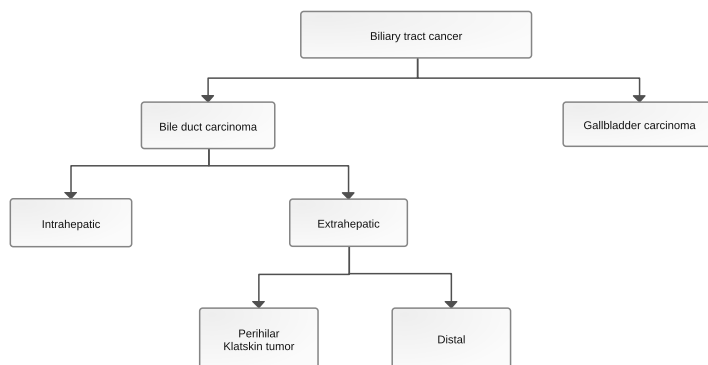
Carcinomas of the Ampulla Vateri (papillary carcinomas) represent a separate family of entities, but have some similarities to distal extrahepatic biliary carcinomas and are also covered by this guideline (see chapter [6.3.1](#))

2 Basics

2.1 Definition and basic information

Biliary tract cancer is a rare and inhomogeneous tumor entity, accounting for less than 1.7% of all malignant tumors [[1](#), [2](#)]. The nomenclature is often inconsistent. For example, the outdated term "cholangiocellular carcinoma" or the term "cholangiocarcinoma" is sometimes used as an umbrella term for all biliary carcinomas, but many authors only use it for carcinomas of the bile ducts or intrahepatic biliary carcinomas. [Figure 1](#) provides an overview of a possible nomenclature.

Figure 1: Nomenclature of biliary tract cancer



The term "cholangiocellular carcinoma" is widely used, but should be avoided, as the purely cholangiocellular origin of these tumors is not sufficiently proven.

2.3 Epidemiology

There are clear geographical differences in the incidence of bile duct carcinomas. They are rare in Europe, Australia and the USA, with an incidence of 0.3-3.5/100,000 inhabitants. In countries with frequent trematode infections of the liver, the incidence is significantly higher [3]. In the case of extrahepatic biliary carcinoma, regional differences are only slight, with an incidence of between 0.5 (Great Britain) and 1.1 (Manitoba, Canada) per 100,000 inhabitants. In western countries, the incidence of intrahepatic biliary carcinomas has increased in recent decades, while the incidence of extrahepatic tumors has decreased.

Gallbladder carcinomas are also rare in Western Europe and the USA, with an incidence of 1.6-2/100,000 inhabitants. In Chile, India and Eastern Europe, they are significantly more common with incidences of up to 35/100,000. Women are affected approx. 4 times more frequently than men. According to autopsy studies, carcinomas of the gallbladder are the most common biliary carcinomas [4].

In Germany, around 8,000 cases of biliary tract cancer are diagnosed every year. This corresponds to approximately 1.7% of all new cancer cases (non-melanoma skin cancer excluded), with the proportion in men being 1.6% and in women 1.9%.

Biliary tract cancer (malignant tumors of the gallbladder (ICD-10: C23) as well as the intrahepatic (C22.1) and extrahepatic (C24) bile ducts) is responsible for around 6% of all cancers of the digestive tract. Both sexes are affected about equally frequently, although the gallbladder is affected significantly more frequently in women (26%) than in men (12%). Almost half of all cases (women 43%, men 52%) affect the extrahepatic bile ducts. According to causes-of-death statistics, an average of around 6,500 deaths per year in recent years (2020-2022) are attributable to biliary carcinomas. The age-standardized rates of new cases and deaths have recently risen slightly in men, but have remained unchanged in women (Figure 1). In both sexes, there has recently been a decline in the incidence of malignant tumors of the gallbladder and an increase in malignancies of the intrahepatic bile ducts (Figure 2).

The mean age of onset (median) is 73 years for men and 76 years for women; the age distribution differs only insignificantly according to localization.

In just under a quarter of all cases, distant metastases are already present at the time of first diagnosis; in the case of tumors of the gallbladder and intrahepatic bile ducts, this proportion is just under a third (extrahepatic bile ducts: 15%).

The relative survival rates, which put the observed survival in relation to survival in the general population of the same age and gender, are between 11% and 22% after 5 years and between 8% and 18% after 10 years, depending on the location (Figure 3). The relative 5-year survival has thus increased by around 3 percentage points over the last 10 years for intrahepatic and extrahepatic bile ducts, while there have been no changes for gallbladder tumors.

Figure 2: Age-standardized rates of new cases and deaths from biliary tract cancer in Germany, by gender (2009-2020/2022, per 100,000 persons, old European standard)

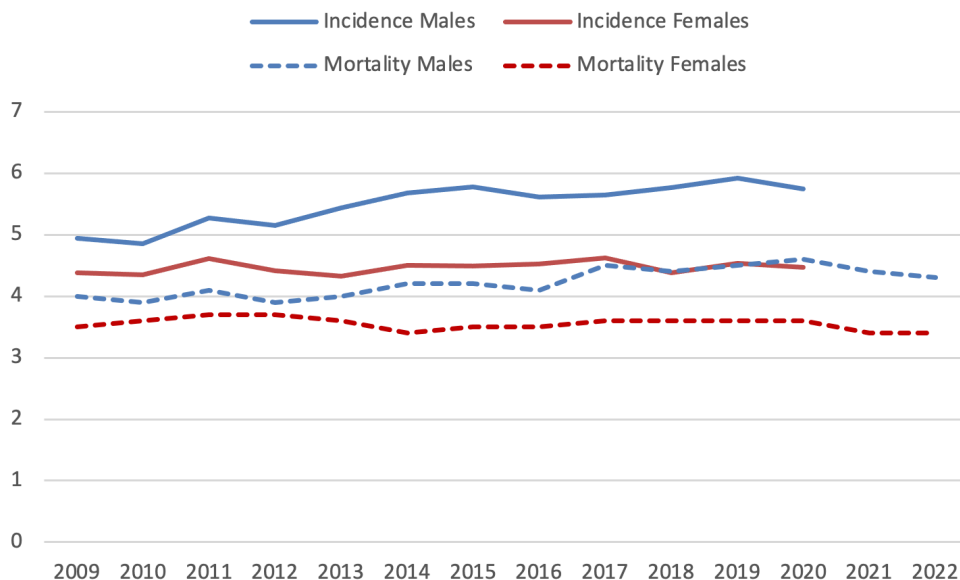


Figure 3: Age-standardized rates of new cases of biliary tract cancer in Germany, by gender and localization (2009-2020, per 100,000 persons, old European standard)

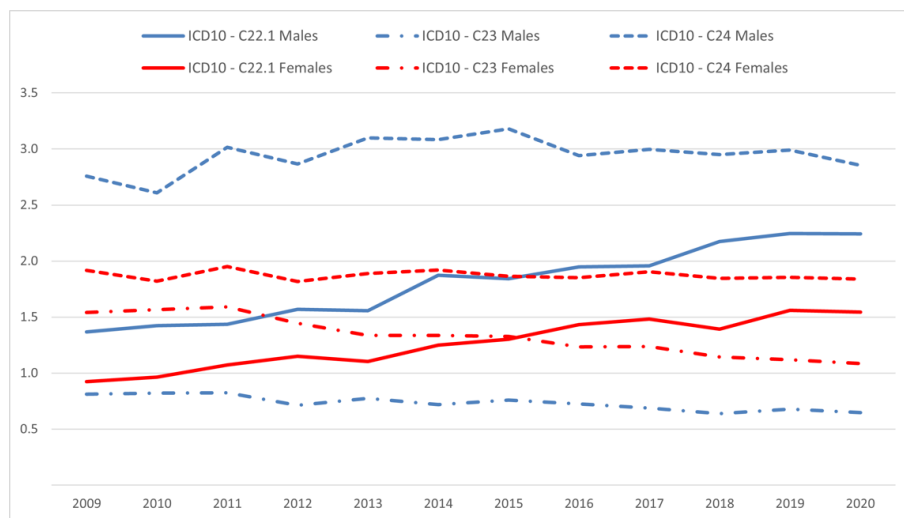
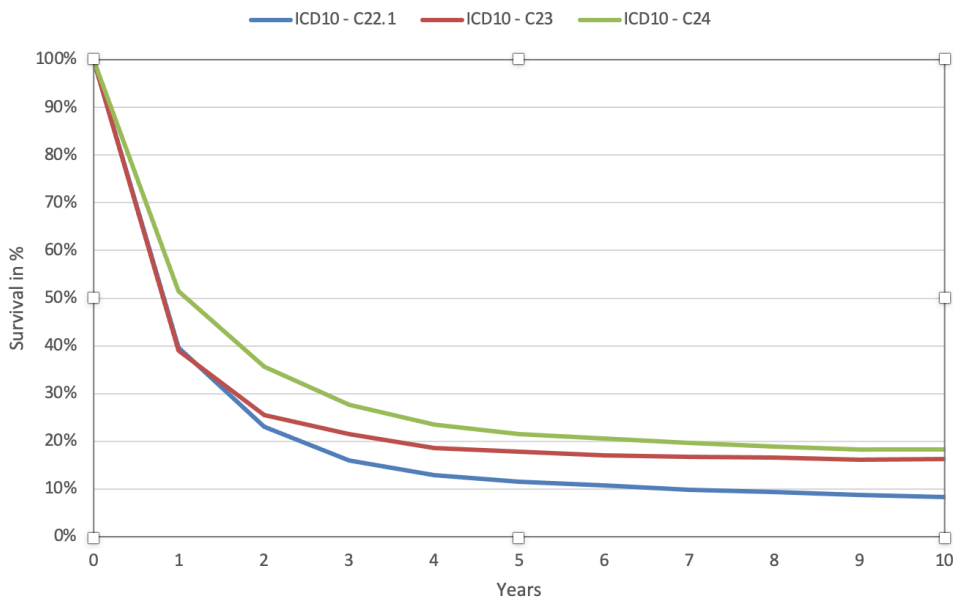


Figure 4: Relative survival rates in Germany up to 10 years after initial diagnosis of biliary tract cancer, by localization (period analysis, selected registries)



2.4 Pathogenesis

The pathogenesis of biliary tract cancer is complex, also depending on the respective localization. Extracellular factors such as proinflammatory cytokines, growth factors, infectious agents or bile acid as well as genetic aberrations with deregulation of intracellular signaling pathways are involved in carcinogenesis, growth and metastasis [3].

Mutations of *IDH1/2*, *EPHA2* or *BAP1*, as well as gene rearrangements or fusions of *FGFR2* can be pathognomonic for intrahepatic cholangiocarcinomas. Mutations of *ARID1B*, *PRKACA* and *BRAF* have been described in extrahepatic cholangiocarcinomas, while mutations of *TP53* or in the *RAS genes* do not occur in a localization-specific manner [9].

2.4.1 Precancerous lesions

Biliary intraepithelial neoplasias (BillIN) are considered to be precursor lesions of large-duct-type intrahepatic cholangiocarcinomas, extrahepatic cholangiocarcinomas and gallbladder carcinomas, which today are divided into a low-grade and a high-grade (with a high risk of progression) category [10].

Intraductal papillary neoplasms of the biliary system (IPNB) are also regarded as pre-neoplasms for extrahepatic bile ducts and for the large-duct type of intrahepatic cholangiocarcinoma. On the basis of the predominant cell type (mixed forms are common), pancreatobiliary IPNBs are discriminated from intestinal, gastric and oncocytic IPNBs; they are also divided into low-grade and high-grade forms, with the risk of progression and, in the case of associated carcinoma, the prognosis differing depending on the constellation. Similar to the pancreas, intraductal oncocytic neoplasms represent a separate tumor entity with characteristic genetic alterations [90]. Further differentiated from these lesions are intraductal tubulopapillary neoplasms of the bile ducts, which also occur in the bile ducts in analogy to the correspondingly named and well-defined lesions of the pancreas [79], although data on these neoplasms is still very sparse. Cholangiocarcinomas of the small duct type can also be associated with ITPN and IPNB [77].

Intracholecystic papillary neoplasia (ICPN, various subtypes) is another precancerous lesion of the gallbladder. In ICPN lesions with a sessile growth pattern and a size of more than 1 cm, malignant transformation is likely [11, 12].

2.5 Risk factors

The risk factors vary depending on the localization. In principle, increased age remains the main risk factor for developing biliary tract cancer in Germany.

The main risk factors for intrahepatic carcinoma of the bile ducts correspond to those for hepatocellular carcinoma, i.e., primarily liver cirrhosis and hepatitis B or C infections. Chronic inflammation of the bile ducts has been identified as a risk factor for extrahepatic carcinoma of the bile ducts, in particular primary sclerosing cholangitis and (other) strictures of the bile ducts, in biliary cysts and Caroli syndrome, as well as the parasitic infections mentioned below in South-east Asia.

The risk of developing carcinoma of the bile ducts is associated with the following factors [13]:

- Chronic infections, parasite infestation (*Opisthorchis viverrini*, *Clonorchis sinensis*)
- Primary sclerosing cholangitis: annual risk 0.5-1.5%, lifetime risk 5-10%
- Hepatolithiasis, choledocholithiasis
- Choledochal cysts
- Caroli syndrome
- Thorotrast as an X-ray contrast agent (no longer in use today)

Other possible risk factors for intrahepatic carcinoma of the bile ducts are hepatitis B and C infections, liver cirrhosis, alcohol and nicotine consumption, steatosis hepatis and diabetes mellitus.

The risk of developing gallbladder carcinoma is increased by the following factors [14]:

- Cholecystolithiasis (significantly increased risk from a stone size of > 3 cm, in the case of cholesterol-containing stones possibly from > 1.5 cm)
- Porcelain gall bladder
- ICPN of the gallbladder (from ≥ 1 cm)
- Primary sclerosing cholangitis
- Chronic infections including *Salmonella* persistent excretors
- Malformations of the bile ducts (e.g., Mirizzi syndrome)
- Obesity

3 Prevention and early detection

3.1 Prevention

The recommendations for the prevention of biliary tract cancer relate to the acquired risk factors identified to date.

3.2 Early detection

No early detection measures have been established in Germany for the asymptomatic population.

Porcelain gallbladder and Caroli syndrome are recognized indications for prophylactic surgical resection as defined precancerous conditions.

In patients with primary sclerosing cholangitis, a screening strategy with CA 19-9 determination and MRI/MRCP (magnetic resonance imaging/magnetic resonance cholangiopancreatography) every 6-12 months can be considered [15].

Patients with gallbladder polyps measuring 6 to 9 mm should undergo at least one annual sonographic check-up. In the "Biliary Cancer: ESMO Clinical Practice Guideline", prophylactic cholecystectomy is recommended from a size of 10 mm and in the event of an increase in size; prospective study data are not available [1].

The German S3 guideline for the treatment of gallstones [16] recommends the following procedure:

- asymptomatic patients with porcelain gallbladder: cholecystectomy
- asymptomatic patients with gallbladder stones > 3 cm in diameter: consider cholecystectomy
- Patients with gallbladder stones and gallbladder polyps \geq 1 cm: cholecystectomy regardless of symptoms.

4 Clinical characteristics

4.1 Symptoms

Intrahepatic biliary carcinoma often remains asymptomatic for a long time; the following symptoms typically occur with locally advanced tumors and/or metastasized cancer:

- Jaundice, cholangitis
- Vomiting, nausea, inappetence
- Upper abdominal pain, often right-sided
- Palpable mass in the right upper abdomen (Courvoisier's sign)
- Weight loss, asthenia, fatigue
- Ascites

Extrahepatic biliary carcinomas cause a bile flow obstruction at an early stage, and a painless jaundice often leads to the diagnosis.

5 Diagnosis

5.2 Diagnostics

5.2.1 Initial diagnosis

Contrast-enhanced cross-sectional imaging (MRI and/or computed tomography) is the method of first choice for (further) clarification of a clinical suspicion and often also enables staging or spread diagnosis [1], see [Table 1](#).

An invasive diagnosis using ERC (endoscopic retrograde cholangiography) as well as forceps and brush cytology or EUS (endoscopic ultrasound) examination with fine needle aspiration cytology is reserved for inconclusive cases or patients with cholestasis and cholangitis and thus requiring decompression of the bile ducts. However, invasive diagnostics using ERC should only be performed in the case of non-distantly metastasized perihilar tumors after surgical presenta-

tion and determination of the overall multidisciplinary, in this case predominantly surgical, treatment strategy.

In patients without relevant cholestasis and with high-grade suspicion of biliary tract cancer on cross-sectional imaging, these invasive measures should be avoided and surgical exploration should be generously indicated.

In patients with tumors assessed as resectable, liver function should be clarified depending on the extent of the tumor and the respective previous morbidities. This is mandatory in the case of intrahepatic tumor localization with planned partial hepatectomy.

In the case of non-resectable biliary tract cancer, histological confirmation is mandatory before initiating treatment.

[Table 1](#) provides an overview of the diagnostic procedures.

Table 1: Diagnostic procedures and staging in biliary tract cancer

Procedure	Remark
Physical examination	
Laboratory (blood)	<ul style="list-style-type: none"> • Blood count, liver and kidney function parameters, coagulation, TSH • Tumor markers CA 19-9, CEA • IgG4 for the differential diagnosis of IgG4-associated cholangitis
Endoscopic retrograde cholangiography (pancreaticography) (ERCP) + brush cytology/fine needle aspiration	<ul style="list-style-type: none"> • If necessary, diagnostic to clarify the spread pattern and, if necessary, cytological confirmation • Therapeutic for cholestasis/cholangitis • In non-metastatic cases without cholangitis only after consultation with hepatobiliary surgeons
CT thorax and abdomen with contrast medium	<ul style="list-style-type: none"> • Method of first choice • Survey of intra-/extrahepatic tumor manifestations • Before planned resection for vascular imaging
Abdominal ultrasound	<ul style="list-style-type: none"> • Supplementary to CT and MRI, often the primary diagnostic procedure
EUS, endosonography	<ul style="list-style-type: none"> • Optional for determining the lymph node status • If necessary, diagnostic in the case of a definable mass along the extrahepatic bile ducts for targeted biopsy.
Cholangioscopy	<ul style="list-style-type: none"> • In individual cases for diagnostic/histological confirmation
MRI abdomen (if necessary + liver-specific contrast agent)	<ul style="list-style-type: none"> • Method of first choice for imaging the bile ducts and detecting tumor spread
MRCP	<ul style="list-style-type: none"> • Optional as a supplement to MRI and ERCP • If Klatskin tumor is suspected • For perihilar tumors during the evaluation of surgical therapy before performing ERCP
PET-CT	<ul style="list-style-type: none"> • In individual cases for staging
Laparoscopy with histology/cytology	<ul style="list-style-type: none"> • Optional for therapy planning in resectable disease and suspected peritoneal carcinomatosis • Optional for assessing the liver (especially in the case of intrahepatic biliary carcinoma or PSC)
Limax, elastography (Fibroscan®) of the liver	<ul style="list-style-type: none"> • To clarify liver function or liver fibrosis/cirrhosis together with liver synthesis parameters
Volumetry of the liver	<ul style="list-style-type: none"> • To estimate the residual liver after resection
Gastroscopy / colonoscopy	<ul style="list-style-type: none"> • For intrahepatic biliary carcinomas to exclude the differential diagnosis of "liver metastasis from gastrointestinal primary"

Legend:

CT - Computed tomography; ERCP - Endoscopic retrograde cholangiopancreatography; EUS - Endoscopic ultrasound examination; MRI - Magnetic resonance imaging; MRCP - Magnetic resonance cholangiopancreatography; PET-CT - Positron emission tomography-computed tomography

In the case of potentially resectable biliary tract cancer, further clarification of liver function using special procedures such as volumetry, Limax® test and elastography (Fibroscan®) may be necessary for surgical planning.

Dynamic contrast MRI is indicated in the imaging of intrahepatic carcinomas. This enables image morphological differentiation from hepatocellular cancer (HCC), for which early arterial contrast agent uptake and "wash out" in the venous contrast agent phase are typical.

5.3 Classification

5.3.1 Classification according to localization

The current TNM classification 8th edition [17] distinguishes, depending on the localization, between carcinomas of the

- Intrahepatic bile ducts
- Carcinomas of the gallbladder and of the Ductus cysticus
- Carcinomas of the perihilar bile ducts (Klatskin tumors)
- Carcinomas of the distal extrahepatic bile ducts
- Carcinomas of the Ampulla Vateri (see chapter 6.3.1)

5.3.1.1 Perihilar tumors / Klatskin tumors: Classification according to Bismuth-Corlette

This classification was developed to assess the extent of infiltration of the hepatic bifurcation and thus resectability. However, it only refers to the longitudinal extent of the manifestation in the bile duct system, see Table 2. This information is not sufficient for the assessment of resectability, which can only be assessed in combination with contrast-based cross-sectional imaging (CT / MRI).

With the diagnostic methods currently available (MRCP and ERC), the extent of the tumor is often underestimated, but also overestimated (20-30% each). Therefore, even a type IV tumor with uncertain and borderline findings is not per se a contraindication for surgical exploration with subsequent resection if indicated. In addition, modern surgical procedures may allow R0 resection of Bismuth type IV tumors in many cases, so that stage Bismuth IV is not a contraindication to surgery. Local contraindications to curative surgery most frequently result from the involvement of arterial vessels.

Table 2: Perihilar/Klatskin tumors: classification according to Bismuth-Corlette

Type	Description
I	Tumor affects the common hepatic duct, but not the hepatic bifurcation
II	Tumor also affects the hepatic fork
IIIa	Tumor affects the hepatic fork and the right main branch
IIIb	Tumor affects the hepatic fork and the left main branch
IV	Tumor affects hepatic fork and both main branches

5.3.1.2 Perihilar/Klatskin tumors: Jarnagin-Blumgart/MSK classification

Neither the TNM/UICC classification nor the Bismuth-Corlette classification are sufficient for conclusively assessing the resectability of extrahepatic bile ducts. The Memorial Sloan-Kettering (MSK) classification of extrahepatic bile duct tumors developed by Jarnagin-Blumgart is more practically useful here. In this classification, MSK T3 tumors are considered non-resectable, see Table 3.

Table 3: Perihilar/Klatskin tumors: Jarnagin-Blumgart classification [18]

Tumor	
T1	Unilateral spread to the 2nd order bile ducts
T2	Unilateral spread to the 2nd order bile ducts and ipsilateral portal vein involvement or atrophy
T3	Spread bilaterally into the 2nd order bile ducts or unilateral spread to the 2nd order bile ducts and contralateral portal vein involvement or atrophy or involvement of the main portal vein trunk

5.3.2 Stages and staging/TNM

The classification of the extent of the primary tumor and metastasis is based on the UICC/AJCC TNM criteria [18]. The TNM criteria are summarized in Tables 4, 6, 8, 10 and 12, the staging is summarized in Tables 5, 7, 9, 11 and 13.

5.3.2.1 Intrahepatic bile duct carcinomas (C22.1)

Regional lymph nodes are

- for the right side of the liver: hilar lymph nodes along the choledochal Ductus choledochus, A. hepatica communis, V. portae and Ductus cysticus, periduodenal and peripancreatic lymph nodes
- for the left side of the liver: hilar and gastrohepatic lymph nodes

Celiac and/or paraaortic and paracaval lymph node metastases are considered distant metastases.

Table 4: TNM classification - Carcinomas of the intrahepatic bile ducts [Wittekind, TNM 8th edition].

Classification	Tumor
T	Primary tumor
T1a	Solitary tumor ≤ 5 cm in largest extension without vascular invasion
T1b	Solitary tumor > 5 cm in largest extension without vascular invasion
T2	Solitary tumor with intrahepatic vascular invasion or multiple tumors with or without vascular invasion
T3	Tumor(s) with perforation of the visceral peritoneum
T4	Tumor with direct invasion of extrahepatic structures
N	Regional lymph nodes
N0	No regional lymph node metastases
N1	Regional lymph node metastases
M	Distant metastases
M0	No distant metastases
M1	Distant metastases

Legend:

Regional lymphadenectomy and histologic confirmation are usually performed on 6 or more lymph nodes

Table 5: Clinical staging according to UICC - Carcinomas of the intrahepatic bile ducts

Stage	T	N	M
I	T1	N0	M0
Ia	T1a	N0	M0
Ib	T1b	N0	M0
II	T2	N0	M0
IIIa	T3	N0	M0
IIIb	T4	N0	M0
	Each T	N1	M0
IV	Each T	Each N	M1

5.3.2.2 Gallbladder and Ductus cysticus carcinomas (C23.0 and C24.0)

Regional lymph nodes are

- hilar lymph nodes along the Ductus choledochus, the Ductus cysticus, the hepatic artery, the portal vein
- celiac lymph nodes
- lymph nodes along the superior mesenteric artery.

Table 6: TNM classification - Carcinomas of the gallbladder and the Ductus cysticus

Classification	Tumor
T	Primary tumor
Tis	Carcinoma in situ
T1a	Tumor infiltrates mucous membrane
T1b	Tumor infiltrates muscular wall layer
T2a	Tumor infiltrates perimuscular connective tissue on the peritoneal side, but no spread beyond the serosa
T2b	Tumor infiltrates perimuscular connective tissue on the liver side, but does not spread into the liver
T3	Tumor perforates serosa (visceral peritoneum) and/or directly infiltrates the liver and/or an adjacent organ/structure, e.g., stomach, duodenum, colon, pancreas, retina, extrahepatic bile ducts
T4	Tumor infiltrates trunk of the portal vein or hepatic artery or infiltrates 2 or more adjacent organs/structures.
N	Regional lymph nodes
N0	No regional lymph node metastases
N1	Metastases in 1-3 regional lymph nodes
N2	Metastases in 4 or more regional lymph nodes
M	Distant metastases
M0	No distant metastases
M1	Distant metastases

Legend:

Regional lymphadenectomy and histologic confirmation are usually performed on 6 or more lymph nodes

Table 7: Clinical staging according to UICC - Carcinomas of the gallbladder and the Ductus cysticus

Stage	T	N	M
Ia	T1a	N0	M0
Ib	T1b	N0	M0
IIa	T2a	N0	M0
IIb	T2b	N0	M0
IIIa	T3	N0	M0
IIIb	T1, T2, T3	N1	M0
IVa	T4	N0, N1	M0
IVb	Each T	N2	M0
	Each T	Each N	M1

5.3.2.3 Perihilar bile duct carcinomas (C24.0)

Perihilar carcinomas of the bile ducts are localized in the extrahepatic bile ducts up to the junction of the Ductus cysticus.

Regional lymph nodes are

- hilar lymph nodes
- pericholedochal lymph nodes in the hepatoduodenal ligament

Table 8: TNM classification - Carcinomas of the perihilar bile ducts

Classification	Tumor
T	Primary tumor
Tis	Carcinoma in situ
T1	Tumor confined to the bile duct with extension into the muscular wall layer or fibrous layer
T2a	Tumor infiltrates beyond the bile duct into the adjacent soft tissue
T2b	Tumor infiltrates the adjacent liver parenchyma
T3	Tumor infiltrates unilateral branches of the portal vein or hepatic artery
T4	Tumor infiltrates the main branch of the V. portae or bilateral branches; or the A. hepatica communis or 2nd order branches bilaterally; or unilateral 2nd order branches of the bile duct with infiltration of contralateral branches of the V. portae or A. hepatica
N	Regional lymph nodes
N0	No regional lymph node metastases
N1	Metastases in 1-3 regional lymph nodes
N2	Metastases in 4 or more regional lymph nodes
M	Distant metastases
M0	No distant metastases
M1	Distant metastases

Legend:

Regional lymphadenectomy and histologic confirmation is usually performed on 15 or more lymph nodes

Table 9: Clinical staging according to UICC - Carcinomas of the perihilar bile ducts

Stage	T	N	M
I	T1a	N0	M0
II	T2a, T2b	N0	M0
IIIa	T3	N0	M0
IIIb	T4	N0	M0
IIIc	Each T	N1	M0
IVa	Each T	N2	M0
IVb	Each T	Each N	M1

5.3.2.4 Distal extrahepatic bile duct carcinomas (C24.0)

These include carcinomas of the bile ducts, which are located distal to the mouth of the Ductus cysticus. Carcinomas of the Ductus cysticus are classified as gallbladder carcinomas.

Regional lymph nodes are

- Lymph nodes along the Ductus choledochus and the A. hepatica,
- Lymph nodes in the direction of the celiac trunk
- Anterior and posterior pancreaticoduodenal lymph nodes
- Lymph nodes along the suspected and superior mesenteric artery

Table 10: TNM classification - Carcinomas of the distal extrahepatic bile ducts

Classification	Tumor
T	Primary tumor
Tis	Carcinoma in situ
T1	Tumor infiltrates the wall of the bile duct ≤ 5 mm
T2	Tumor infiltrates the wall of the bile duct 6-12 mm
T3	Tumor infiltrates the wall of the bile duct >12 mm
T4	Tumor infiltrates Truncus coeliacus, A. mesenterica superior and/or A. hepatica communis
N	Regional lymph nodes
N0	No regional lymph node metastases
N1	Metastases in 1-3 regional lymph nodes
N2	Metastases in 4 or more regional lymph nodes
M	Distant metastases
M0	No distant metastases
M1	Distant metastases

Legend:

Regional lymphadenectomy and histologic confirmation are usually performed on 12 or more lymph nodes

Table 11: Clinical staging according to UICC - Carcinomas of the distal extrahepatic bile ducts

Stage	T	N	M
Ia	T1	N0	M0
IIa	T1	N1	M0
	T2	N0	M0
IIb	T2	N1	M0
	T3	N0, N1	M0
IIIa	T1, T2, T3	N2	M0
IIIb	T4	Each N	M0
IV	Each T	Each N	M1

5.3.2.5 Carcinoma of the Ampulla Vateri (C24.1)

The regional lymph nodes correspond to those of the pancreatic head, located at

- Ductus choledochus
- A. hepatica communis and V. portae
- pyloric, infrapyloric, subpyloric
- proximal mesenteric, celiac
- posterior and anterior pancreatoduodenal
- V. mesenterica superior
- right lateral wall of the superior mesenteric artery

Lymph nodes of the splenic hilus and the tail of the pancreas are not considered regional and are classified as distant metastases.

Table 12: TNM classification - Carcinoma of the Ampulla Vateri

Classification		Tumor
T		Primary tumor
	Tis	Carcinoma in situ
	T1a	Tumor limited to Ampulla Vateri or Sphincter Oddi
	T1b	Tumor infiltrates beyond the Sphincter Oddi (perisphincteric invasion) and/or into the submucosa of the duodenum
	T2	Tumor infiltrates the muscularis propria of the duodenum
	T3a	Tumor invades the pancreas ≤ 0.5 cm
	T3b	Tumor invades the pancreas > 0.5 cm or infiltrates the peripancreatic soft tissue without involvement of the celiac trunk or the superior mesenteric artery
	T4	Tumor involving the vessel walls of the celiac trunk or the superior mesenteric artery or the common hepatic artery
N		Regional lymph nodes
	N0	No regional lymph node metastases
	N1	Metastases in 1-2 regional lymph nodes
	N2	Metastases in 3 or more regional lymph nodes
M		Distant metastases
	M0	No distant metastases
	M1	Distant metastases

Legend:

Regional lymphadenectomy and histologic confirmation are usually performed on 12 or more lymph nodes

Table 13: Clinical staging according to UICC - Carcinoma of the Ampulla Vateri

Stage	T	N	M
Ia	T1a	N0	M0
Ib	T1b, T2	N0	M0
IIa	T3a	N0	M0
IIb	T3b	N0	M0
IIIa	T1a, T1b, T2, T3	N1	M0
IIIb	Each T	N2	M0
	T4	Each N	M0
IV	Each T	Each N	M1

5.3.3 Histological subtypes

5.3.3.1 General aspects of biliary differentiated cholangiocarcinoma

The most common histological subtype of cholangiocarcinoma in all localizations is adenocarcinoma with biliary differentiation ("biliary-type cholangiocarcinoma"). These tumors usually show a ductal-tubular growth pattern with variable diameters of the neoplastic glands (see also below) and often considerable stromal dysplasia. Immunohistologically, these tumors usually express MUC1, CK7, CK19 and CA19-9. These tumors are graded as well, moderately or poorly

differentiated cholangiocarcinomas - however, according to not exactly defined criteria depending on morphological proximity to normal cholangiolar cells/ducts.

5.3.3.2 Gallbladder carcinomas

Histologically, the vast majority of gallbladder carcinomas are adenocarcinomas; the most common subtype and the typical gallbladder carcinoma in particular is biliary-differentiated adenocarcinoma with its characteristic small ductal "pancreatobiliary" morphology. In addition, intestinal-differentiated adenocarcinomas (with intestinal-imposing cells, rare), mucinous adenocarcinomas (more than 50% of the tumor components form extracellular mucin), clear cell adenocarcinomas and the poorly cohesive adenocarcinoma associated with signet ring cells as well as the very rare hepatoid carcinoma have also been described. Partially, the different morphologies have prognostic relevance and are associated with different degrees of aggressiveness (for example, poorly cohesive and mucinous tumors are prognostically unfavorable).

Mixed tumors such as adenosquamous carcinoma also occur in the gallbladder. Focal squamous differentiation is quite common in adenocarcinomas of the gallbladder, but adenosquamous carcinoma is only diagnosed when 25% of the tumor is squamous. Also described are extremely rare mixed neuroendocrine-non-neuroendocrine neoplasms (MiNEN), which show a broad spectrum of aggressiveness depending on differentiation.

In addition to adenocarcinoma differentiation, pure squamous cell carcinomas and - also very rarely - "pure" neuroendocrine neoplasms are also seen extremely rarely. Finally, undifferentiated carcinomas (without lineage classification) and sarcomatoid carcinomas are also extremely rare tumor types of the gallbladder.

For the sake of completeness, it should also be mentioned that mesenchymal tumors and lymphomas can also occur as primary tumors in this location. However, these tumors - as well as neuroendocrine neoplasms - are not addressed in this guideline.

5.3.3.3 Carcinomas of the extrahepatic bile ducts

Extrahepatically, the vast majority of epithelial biliary tract tumors are adenocarcinomas; here too, the biliary differentiated subtype is the classic extrahepatic cholangiocarcinoma. Variants exist as intestinal, foveolar, mucinous, signet-ring cell, clear cell, pyloric-glandular, hepatoid and micropapillary adenocarcinomas, each being rare to very rare.

Mixed tumors are also described here, particularly in the sense of adenosquamous carcinomas as well as undifferentiated and sarcomatoid variants. Non-epithelial tumors and neuroendocrine neoplasms (see gallbladder) also occur.

5.3.3.4 Carcinomas of the intrahepatic bile ducts

By definition, carcinomas of the intrahepatic bile ducts only include "pure" cholangiocarcinomas. All other intrahepatic carcinomas, including mixed tumors with cholangiocellular-hepatocellular differentiation, undifferentiated carcinomas and neuroendocrine neoplasms, represent independent entities.

Intrahepatic cholangiocarcinomas belong to the group of adenocarcinomas with a ductal "pancreatobiliary" phenotype. There are basically two types.

The large duct type of intrahepatic cholangiocarcinoma usually manifests close to the hilus, originates from the larger bile ducts and peribiliary glands and shows a somewhat more large-glandular ductal-tubular growth pattern. These tumors are often associated with BillNs or IPNBs

(see chapter [2.4.1.](#), Precancerous lesions), often show a periductal infiltration pattern and sometimes contain mucin. These tumors are associated with parasitic bile duct diseases, hepatolithiasis and primary sclerosing cholangitis. Histological variants as described for the extrahepatic bile ducts also occur in this subtype.

In contrast, there is the small-duct type of intrahepatic cholangiocarcinoma, which manifests itself in the periphery and usually forms a coherent tumor mass. These tumors are thought to originate from ductal hepatic structures or hepatic progenitor cells, show a small ductal and ductal growth pattern, do not produce mucin and are rarely associated with the common precursor lesions for cholangiocarcinoma. Associations with non-biliary cirrhosis and viral hepatitis may be present. Subtypes of the small-duct type are cholangiolocarcinoma and intrahepatic cholangiocarcinoma with ductal plate malformation pattern. Mixed forms occur. IDH1/2 and BRAF mutations as well as FGFR2 fusions are typical for the small-duct type.

5.3.3.5 Carcinomas of the Ampulla Vateri, papillary carcinomas

For carcinomas of the Ampulla Vateri, see chapter [6.3.1.](#)

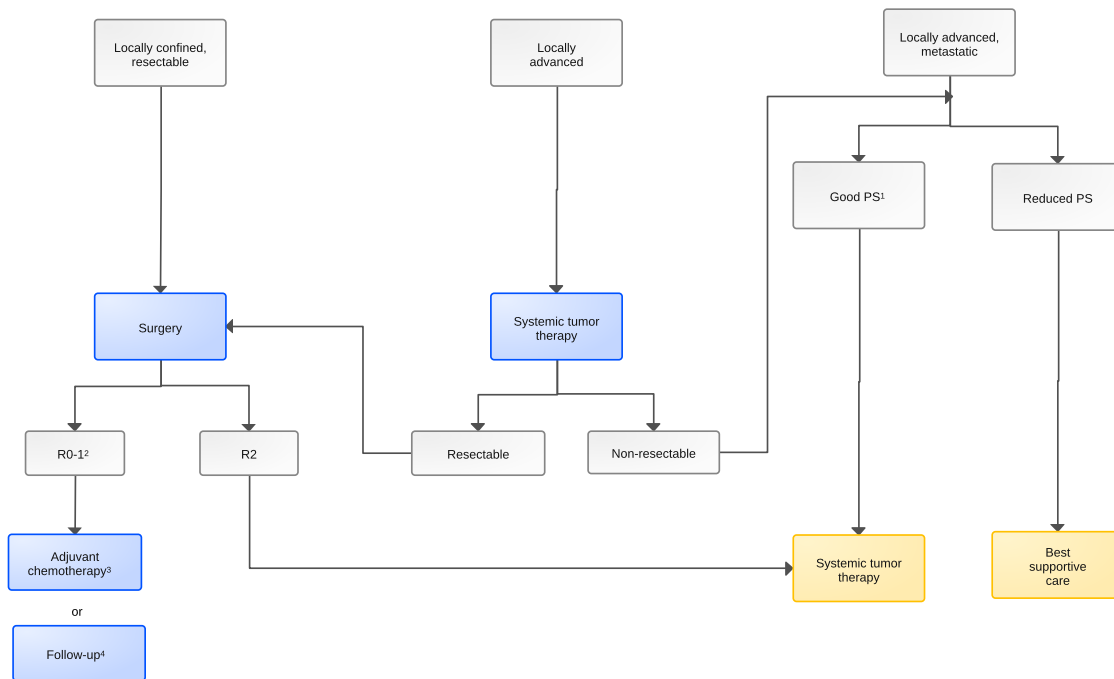
6 Therapy

6.1 Treatment structure

Due to the complex treatment options and the rarity of the diseases, recommendations should always be discussed and decided on a multidisciplinary basis.

A treatment algorithm is shown in [Figure 5.](#)

Figure 5: Algorithm for primary treatment of biliary carcinoma



Legend:

■ curative intended therapy; ■ non-curative intended therapy;

¹ PS – performance score;

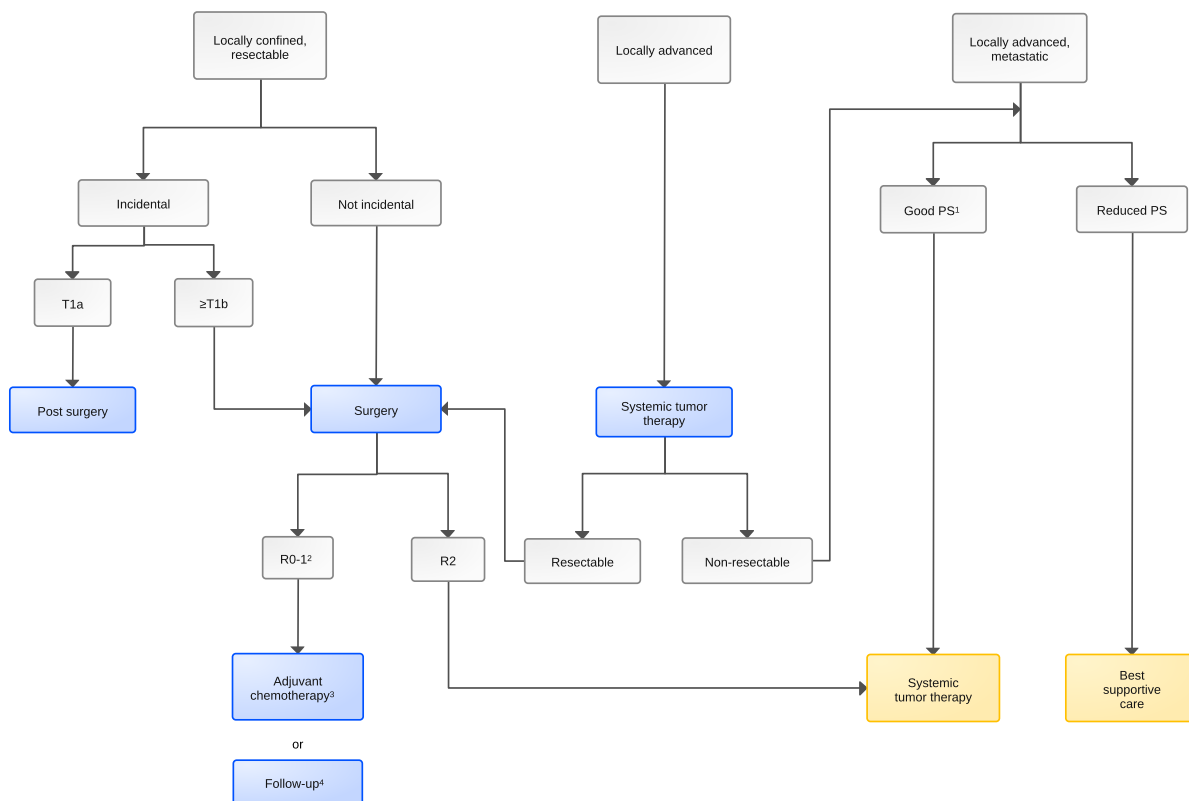
² R - classification of the condition after surgical resection of the primary tumor;

³ DPD deficiency must be excluded before fluoropyrimidine-containing chemotherapy [28], [Link to https://www.dgho.de/publikationen/stellungnahmen/gute-aerztliche-praxis/dpd-testung/dpd-positions-papier-2020-konsens_logos_final];

⁴ Follow-up - for contraindications to adjuvant chemotherapy

In two thirds of all cases, gallbladder carcinomas are incidental findings after a cholecystectomy performed for benign reasons (so-called incidental gallbladder carcinomas), see Figure 6.

Figure 6: Algorithm for primary treatment of gallbladder carcinoma



Legend:

■ curative intended therapy; ■ non-curative intended therapy

¹ PS – performance score

² R - Classification of the condition after surgical resection of the primary tumor

³ DPD deficiency must be excluded before fluoropyrimidine-containing chemotherapy [28], link to https://www.dgho.de/publikationen/stellungnahmen/gute-aerztliche-praxis/dpd-testung/dpd-positionspapier-2020-konsens_logos_final

⁴ Follow-up - for contraindications to adjuvant chemotherapy

6.1.1 Stage I-III

6.1.1.1 Surgical resection in stages I to III

Complete surgical resection is the only potentially curative therapeutic approach. The aim of the procedure must be an R0 resection. Depending on the stage and selection, 5-year survival rates of 20-50% can be achieved [10]. Contraindications to surgical resection may include bilateral or multifocal manifestations with a non-curative approach and comorbidities. As a rule, the treatment decision should be made in a multidisciplinary tumor conference with the participation of an experienced hepatobiliary surgeon. Even if the involvement of regional lymph nodes is associated with a less favorable prognosis, this is not a contraindication for resection.

Preoperative histological confirmation is not necessary for resectable tumors with clear clinical and imaging findings. This is often difficult, especially in the case of perihilar tumors, as there is a high rate of false negative findings. However, differential diagnoses such as the rare IgG4-associated cholangitis must be taken into account.

The resectability of perihilar tumors is assessed on the basis of bile duct diagnostics (MRCP, ERC if necessary) and the local situation on MRI/CT (vascular involvement, atrophy of a liver lobe).

Neither the UICC classification nor the Bismuth-Corlette classification are suitable for conclusively assessing resectability. The Memorial Sloan-Kettering classification (MSK) of extrahepatic

bile duct tumors developed by Janargin-Blumgart is more practicable here. In this classification, MSK T3 tumors are considered no longer resectable (see [Table 4](#))

The type and extent of surgery and the associated lymph node dissection depend on the respective localization of the tumor and any affected lymph nodes, see chapter [6.2.1 Treatment modalities - Resection](#) [20].

- For intrahepatic tumors, partial liver resection by segmental resection, hemihepatectomy or extended hemihepatectomy are the methods of choice. In the case of extensive tumors whose resection leads to a significant reduction in the remaining liver volume, ipsilateral preoperative portal vein embolization may be necessary to augment the remaining liver tissue.
- In the case of perihilar carcinomas, hemihepatectomies or extended hemihepatectomies are usually performed, often in conjunction with preoperative portal vein embolization. The question of the exact extent of infiltration of the bile ducts can often only be clarified during the operation (by means of a frozen section examination of the bile duct incision margin). However, histological clarification (R0 or R1) is often only possible at a stage where resection has already taken place. If a subsequent resection is possible after R1 resection of the bile duct, this should be performed.
- For extrahepatic distal biliary carcinomas, a pylorus-preserving pancreaticoduodenectomy (PPPD) or a conventional pancreatic head resection according to Kausch-Whipple is the standard treatment procedure.
- In the case of incidental gallbladder carcinoma, an oncological resection should be performed within the next 45 days from stage \geq T1b [21]. This radical cholecystectomy includes a liver resection, usually as a wedge resection of the gallbladder bed with a safety margin of 3 cm in the liver or an anatomical resection of liver segments IVb/V as a so-called bisegmentectomy. This technique is sufficiently radical, especially for T1b and T2 tumors; larger resections are usually required for T3 tumors. In addition, a dissection of the locoregional lymph nodes in the hepatoduodenal ligament must be performed. Complete staging to exclude distant metastases should be performed prior to oncological resection.

In recent years, postoperative morbidity and mortality have been reduced to less than 5%. The main complications may be biliary fistulas, intra-abdominal abscesses and hepatic insufficiency.

Laparoscopic surgery has become increasingly important for hepatic resections in recent years due to comparable mortality and reduced hospitalization time, transfusion frequency and complication rate [22]. This does not apply to surgical procedures on the pancreatic head and liver operations requiring complex bile duct reconstruction.

The value of preoperative bile drainage for cholestasis using ERC has not been conclusively clarified, but is often unavoidable, especially in the case of perihilar tumor localization, which then requires extended partial hepatectomy. This should be considered in cases of hyperbilirubinemia (> 10 mg/dl), secondary complications such as cholangitis or surgery that cannot be performed promptly [1]. PTCD should only be performed in exceptional cases in order to minimize the risk of tumor cell spread.

6.1.1.2 Adjuvant therapy

Based on the currently available data from the BILCAP study, see chapter [6.1.1.2.1](#), patients should be offered adjuvant therapy with capecitabine for 6 months after complete curative resection (R0/1) of a biliary carcinoma.

6.1.1.2.1 Adjuvant chemotherapy

The BILCAP study is the first data from a randomized phase III study to demonstrate the benefit of adjuvant chemotherapy with the oral fluoropyrimidine capecitabine compared to follow-up alone: Although an increase in overall survival was shown for the ITT population, this was not statistically significant (median 15 months; HR 0.80; $p = 0.097$) [25]. However, in the sensitivity analysis after adjustment for gender, lymph node status and degree of differentiation, post-operative treatment with capecitabine for 6 months showed a significant improvement in overall survival (median 17 months, HR 0.71; $p=0.01$). In the Japanese ASCOT/JCOG1202 study, adjuvant therapy with a fluoropyrimidine - S1 vs follow-up alone also showed a significant improvement in survival (3-year survival 77.1 vs 67.6%; HR 0.69; $p=0.0080$).

In contrast, a French randomized phase III study (PRODIGE-12-ACCORD 18-UNICANCER GI), which included 196 patients with intrahepatic and extrahepatic tumors and gallbladder carcinomas, showed no improvement in survival with adjuvant chemotherapy with gemcitabine plus oxalipatin compared to follow-up alone [26].

In another recently published randomized study (BCAT), 225 patients with extrahepatic biliary carcinoma were treated with gemcitabine or underwent follow-up alone. After a median follow-up of 6.6 years, there was no difference in overall survival (HR 1.01, $p=0.964$) [27].

The data from the ACTICCA trial (NCT02170090 Gemcitabine/Cisplatin versus Capecitabine adjuvant), which will be fully recruited in 2024, will add important information to further define the standard for adjuvant chemotherapy in patients with biliary carcinoma.

Prior to fluoropyrimidine-containing chemotherapy, genetic polymorphisms in the four most important dihydropyrimidine dehydrogenase (DPD) gene loci must be excluded in order to rule out a clinically relevant variant and thus a deficiency (DPYD) [28], https://www.dgho.de/publikationen/stellungnahmen/gute-aerztliche-praxis/dpd-testung/dpd-positionspapier-2020-konsens_logos_final.

6.1.1.2.2 Adjuvant radio- and radiochemotherapy

Due to the high rate of local recurrence and distant metastases after surgical resection, there is a great need for adjuvant local therapy, possibly supplemented by effective systemic therapy. Data is available from several retrospective studies on adjuvant radiotherapy. The meta-analysis showed a reduction in mortality, in the exploratory subgroup analysis especially in patients with positive lymph nodes and in patients after R1 resection [29]. The meta-analysis of 8 studies on adjuvant radiochemotherapy also indicated a reduction in mortality [30], here also primarily in patients not achieving R0 resection.

Data from high-quality phase III trials are not available, meaning that adjuvant radiotherapy or radiochemotherapy is not current standard. An overview of the currently available, predominantly retrospective data can be found in chapter 6.2.2 Therapy modalities - radiotherapy.

6.1.1.3 Neoadjuvant/preoperative therapy

Neoadjuvant treatment strategies are currently part of individual treatment concepts and are being further investigated as part of clinical trials. The German GAIN study on perioperative (neoadjuvant/adjuvant) chemotherapy for gallbladder carcinomas and intra- and extrahepatic biliary carcinomas is currently underway (NCT03673072). In retrospective evaluations, it was shown that preoperative chemotherapy enabled non-resectable or borderline resectable cases

to undergo secondary curative resection. In the largest case series to date, 39 of 74 primarily non-resectable intrahepatic biliary carcinomas (cM0) could be resected after various preoperative therapies. The overall survival of this group did not differ from the primarily resectable group [31]. Therefore, in suitable cases, initial chemotherapy in the sense of conversion therapy can be considered, and the response and the possibility of secondary resection should be checked regularly during chemotherapy. This currently mainly concerns patients with borderline resectable tumor status, without a precise definition currently being available.

6.1.2 Stage IV biliary tract cancer

The therapeutic approach is palliative. Treatment of first choice is systemic therapy, possibly supplemented by local and symptomatic procedures, see [Figure 7](#). Histological or cytological confirmation of the diagnosis is required before initiating treatment. The indication for treatment depends on the patient's general condition, previous treatment, symptoms, specific comorbidity and preference.

Since targeted drugs are now also available for biliary tract cancer from the second line onwards, early, targeted molecular pathological testing is recommended. This includes

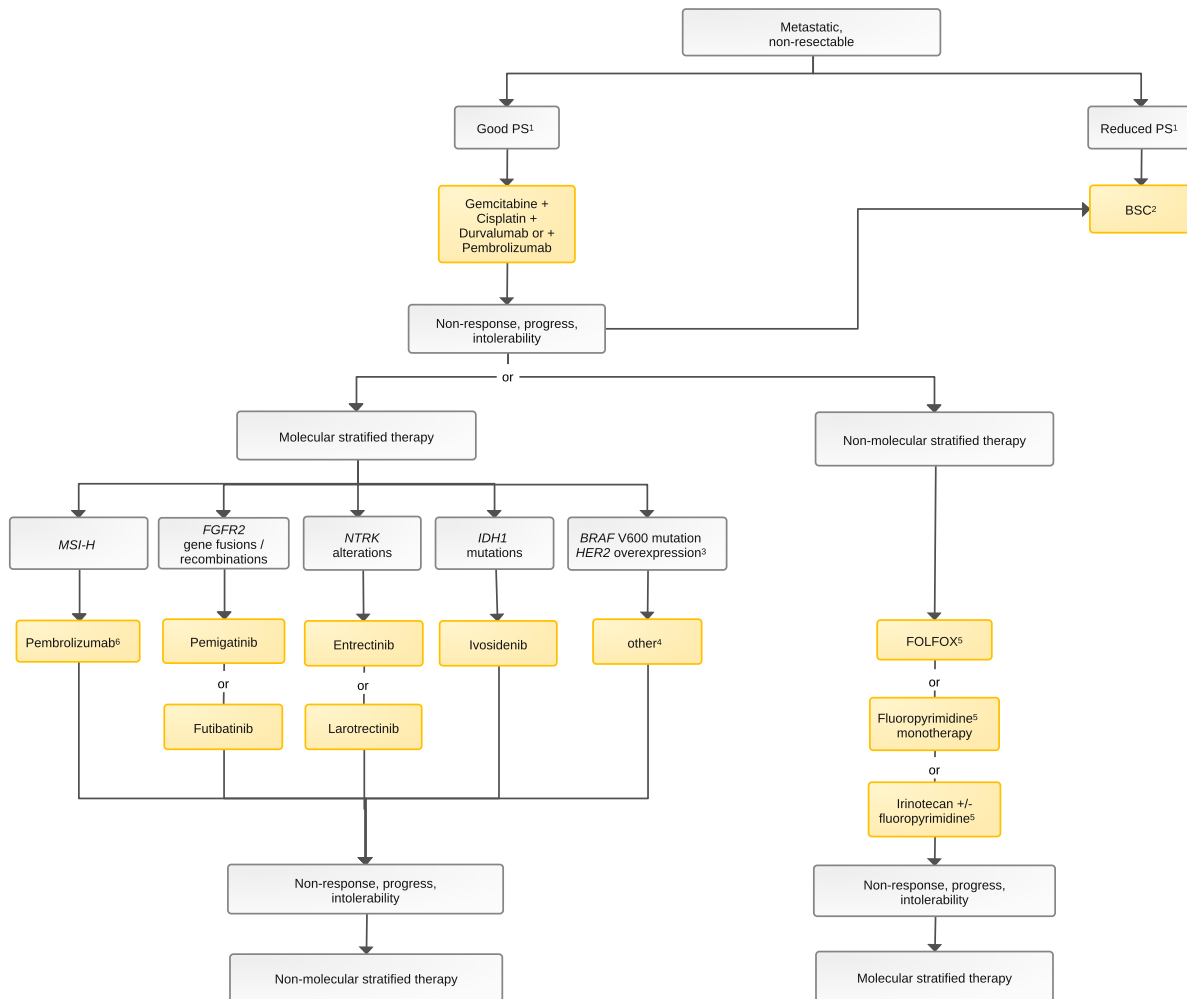
- FGFR2 gene fusions and rearrangements in intrahepatic biliary carcinomas
- IDH1 mutations
- NTRK fusions for intrahepatic biliary carcinomas
- Microsatellite instability/defective mismatch repair (MSI-H/dMMR)

Further analyses as a basis for the use of targeted drugs outside of the marketing authorization (off-label indication) are

- BRAF V600 mutations
- HER2 overexpression and amplification

Knowledge of the therapeutic options enables optimal management and should take place as early as possible in the course of the disease.

Figure 7: Treatment algorithm for stage IV biliary tract cancer



Legend:

non-curative intended therapy;

¹ PS - performance score

² BSC - Best Supportive Care

³ There are targeted drugs for these molecular aberrations, but no approval for the European Union

⁴ Options for off-label indications: BRAF V600 mutations - dabrafenib + trametinib, HER2 overexpression: see chapter 6.1.2.1.4.5

⁵ DPD deficiency must be ruled out before fluoropyrimidine-containing chemotherapy [28], [link to https://www.dgho.de/publikationen/stellungnahmen/gute-aerztliche-praxis/dpd-testung/dpd-positionspapier-2020-konsens_logos_final]

^{6if} no previous treatment with immunotherapy or previous treatment with immunotherapy in the past

6.1.2.1 Systemic tumor treatment - stage IV

6.1.2.1.1 First-line therapy

When determining the indication for systemic therapy, the patient's general condition, comorbidities, patient preferences and the toxicity of the planned regimens must be taken into account. Resection of the primary tumor in a metastatic situation is not recommended [1, 2]. The response to chemotherapy should be regularly monitored by imaging, usually CT thorax and abdomen or other suitable cross-sectional imaging techniques.

For palliative first-line therapy, the standard of care is the combination of immunotherapy and chemotherapy. In the TOPAZ-1 study, the combination of chemotherapy with gemcitabine and cisplatin (GemCis) and the PD-L1 inhibitor durvalumab led to a significant improvement in median overall survival (12.8 vs 11.5 months; HR 0.8; p=0.021) [85]. In the TOPAZ-1 study,

chemotherapy was discontinued after 6 months and maintenance therapy with durvalumab (every 4 weeks) was added). These data are supported by the parallel study KEYNOTE-966, in which the combination of gemcitabine and cisplatin with pembrolizumab was investigated (median overall survival 12.7 vs 10.9 months; HR 0.83; $p=0.0034$) [83]. In contrast to the TOPAZ-1 study, treatment with gemcitabine and pembrolizumab could be continued after 6 months in the KN-966 study. This means a further development of the long-term treatment standard of the well-tolerated combination of gemcitabine 1000 mg/m² and cisplatin 25 mg/m² on days 1,8 with repetition on day 22 analogous to the ABC-02 study [32]. Both checkpoint inhibitors are recommended for combination with GemCis in the first line and are approved for this indication.

If renal function is impaired, oxaliplatin can be used instead of cisplatin [2, 88].

The benefit of adding check point inhibition to doublet chemotherapy is small in the delta, but is remarkable, as previous studies on triplet therapy with conventional chemotherapy, such as PRODIGE 38 AMEBICA with FOLFIRINOX (randomized phase II against Cis/Gem) [87] or Gemcitabine/Cisplatin +/- nab- Paclitaxel (SWOG 1815 phase 3) [89] were negative and the triplet combination GemCis + S1 from the KHBO1401-MITSUBA has also not established itself [82].

6.1.2.1.2 Second-line therapy

A meta-analysis of more than 700 patients with biliary tract cancer showed a moderate benefit from second-line therapy with a median progression-free survival of 3 months and a median overall survival of 7 months. The response rate in this analysis was 8%, the disease control rate 50% [39].

In a retrospective Canadian case series, 96 (25%) of 378 patients received second-line therapy. Among those, there were more women than men, more younger patients (< 60 years) and patients with a progression-free survival of more than 6 months. Positive prognostic factors in this evaluation were combination chemotherapy and a good general condition (ECOG PS <2) [40]. In a recent evaluation of approximately 800 patients with biliary tract cancer who had received second-line chemotherapy between 2003 and 2016, a good performance status was confirmed as a positive prognostic factor as well as the effectiveness of first-line therapy, CA 19-9 and previous tumor surgery [41].

For second-line therapy, data from the randomized phase III ABC-06 trial are available [34]. Here, the combination of oxaliplatin and 5-FU (mFOLFOX) led to a significant improvement in overall survival compared to active symptom control (ASC) in 162 patients included (HR 0.69, $p=0.031$; median OS 6.2 versus 5.3 months; 6- and 12-month survival rates 50.6% and 25.9% versus 35.5% and 11.4%). This indicates that mFOLFOX can be considered a standard second-line therapy. It should be noted that in the ABC-06 study, pre-treatment with GemCis was generally limited to 6 months and therefore does not correspond to the German treatment reality, in which treatment is often continued until progression.

Alternatively, monotherapy (5-FU/LV, capecitabine or irinotecan) or combination therapies consisting of 5-FU/LV or capecitabine in combination with irinotecan or capecitabine and oxaliplatin [35] can be used.

In recently published data on irinotecan, efficacy was partially demonstrated, however, with overall conflicting data: the combination of irinotecan + capecitabine versus irinotecan led to an extension of survival time (10.1 vs. 7.3 months) in a randomized phase II study from China with 60 patients [36]. The combination of 5FU/LV + liposomal irinotecan also showed a significant improvement in median overall survival compared to 5FU/LV in the randomized phase IIb NIFTY study from South Korea with 178 patients (8.6 vs 5.5 months; HR 0.68) [37]. However,

there was no improvement in survival in the German Naliricc study with an identical approach (randomized comparison of liposomal irinotecan+5FU/LV vs 5FU/LV) [91]. In a phase II study from India with 98 patients with adenocarcinoma of the gallbladder, the survival benefit of adding capecitabine to irinotecan compared to irinotecan monotherapy was also not confirmed [38], indicating that monotherapy may also be a valid option.

Whenever possible, patients should be treated within the framework of clinical trials.

6.1.2.1.3 Third-line therapy

There is no evidence-based data available. Treatment decisions must be made on an individual basis.

6.1.2.1.4 Targeted therapeutic approaches

Current studies show that in up to 50% of patients with biliary tract cancer, genetic alterations can be detected for which targeted therapies have already been approved or are currently being investigated in clinical trials [42, 84]. We discriminate between genetic alterations for which targeted drugs are approved by the EMA and alterations for which off-label use is possible, see also chapter 6.1.2.

The early analysis of genetic alterations enables optimal management.

6.1.2.1.4.1 FGFR2 gene fusions and rearrangements

Approximately 15% of intrahepatic biliary carcinomas exhibit alterations of the fibroblast growth factor receptor (FGFR), which lead to the activation of various tumor-immanent signaling pathways such as MAPK, PIK3/AKT/MTOR and JAK/STAT. To date, the efficacy of FGFR inhibitors has been demonstrated primarily for FGFR2 translocations. In the single-arm FIGHT 2 study, an objective response rate of 35.5% was shown for patients with FGFR2 fusions or rearrangements after at least one prior therapy (38/146 patients, 3 with complete and 35 with partial remission) [43]. Similar efficacy was shown for the next-generation FGFR1-4 inhibitor futibatinib [78], also in a single-arm study with 103 patients included (ORR 42%, PFS 9.0 months, OS 21.7 months).

These data led to the approval of pemigatinib and futibatinib for this patient subgroup. The selective FGFR inhibitor infigratinib (BGJ398) also showed response rates of up to 40% and a disease control rate of 83% in pretreated patients with translocations of FGFR2 [44].

6.1.2.1.4.2 IDH1 mutations

Mutations of IDH1 are present in approx. 15% of all intrahepatic biliary tract cancer. In the Clar-IDHy trial, a randomized double-blind phase III study, a significant improvement in progression-free survival was shown for the selective oral IDH1 inhibitor ivosidenib (HR 0.37; median 2.7 vs 1.4 months $p < 0.0001$). Overall survival was also prolonged, but not statistically significant (HR 0.69; median 10.3 vs. 7.5 months; $p = 0.06$), however, in a cross-over study design. The disease control rate was 53% for ivosidenib versus 28% for placebo. Ivosidenib has been approved in Germany for the treatment of the IDH1 R132 mutation since 2023 [48]. Similar to hematological diseases (AML) or gliomas, IDH2 alterations also occur, albeit less frequently, either primarily or as a resistance mechanism. Here, off-label therapies with corresponding substances should be considered, such as enasidenib-mIDH2 variants R140Q, R172K and R172S (enasidenib approved by the FDA in 2017, European marketing authorization application withdrawn in

2019) or vorasidenib against mLDH1/2 (INDIGO study ASCO 2023, EMA approval for diffuse gliomas planned for 2024).

6.1.2.1.4.3 BRAF V600 mutations

In BRAF V600E mutated biliary tract cancer (approx. 5%, especially intrahepatic biliary carcinomas), the combination of MEK and BRAF inhibition (trametinib and dabrafenib) showed clinically relevant efficacy in 43 patients with an ORR of 51% (22/43) and an mPFS of 9 months and mOS of 14 months [49]. The combination of cobimetinib + vemurafenib also showed efficacy in the TAPUR basket study with an ORR of 57% and DCR of 68% [93]. Data from a randomized study and approval are not yet available.

6.1.2.1.4.4 HER2/neu - overexpression, - mutation, - amplification

10-27% of extrahepatic bile duct and gallbladder carcinomas show overexpression of HER2/neu. Data are available from various single-arm (basket) studies with small case numbers on HER inhibition in patients with pre-treated, HER2-amplified and/or overexpressing biliary tract cancer:

- Trastuzumab plus pertuzumab (My Pathway study): n=39, ORR 23%, median PFS 4.0 months [50]
- Neratinib (for HER2 mutated): n=25, ORR 16%, median PFS 2.8 months [81]
- Trastuzumab-deruxtecan: n=22, ORR 36%, median PFS 5.1 months [86]
- Tucatinib + trastuzumab: n=29, ORR, 47%, median PFS 5.5 months [85]
- Zanidatamab: n=80, ORR 41%, median PFS 5.5 months [80]

It should be noted that "Her2 positivity" is not defined in the same way in all studies:

In the MyPathway study (trastuzumab + pertuzumab), patients with immunohistochemistry (HER2 overexpression based on IHC3+ staining), fluorescence in situ hybridization or chromogenic in situ hybridization (*HER2* amplification based on *HER2:CEP17* ratio >2-0 or *HER2* copy number >6-0), or next-generation sequencing (*HER2* amplification based on copy number gain) were defined as positive. In the HERIZON-BTC-01 study on zanidatamab, the classic definition was IHC3+ or IHC2+ / amplification with ISH. In the tucatinib+trastuzumab study (SGN-TUC-019), patients were defined as Her2+ if IHC3+ or IHC2+ and amplification was performed by ISH or NGS. Of note, the rates of intrahepatic carcinomas in the last two studies mentioned were 23% and 28% respectively, which is not consistent with the previous data, which showed increased HER2 expression in gallbladder and extrahepatic carcinomas in particular. In the IIT-T-DxD study HERB (trastuzumab deruxtecan (T-DXd), the classic definition of IHC3+ or IHC2+ and amplification by ISH was again used, and separately the definition of Her2 low (HER2-low-expressing: IHC/ISH status of 0/+, 1+/-, 1+/+, or 2+/-) [86].

6.1.2.1.4.5 Microsatellite instability (MSI-H/dMMR)

In analogy to other gastrointestinal tumors, patients with microsatellite instability (mismatch-repair deficiency) respond very well to inhibition of PD-L1 with pembrolizumab during progression under chemotherapy [51], although this is only present in approx. 1% of biliary tract cancer. Pembrolizumab is approved for pre-treated patients from second-line therapy onwards. In the context of the current standard use of immunotherapy in first-line therapy in combination with gemcitabine and cisplatin, renewed monotherapy with pembrolizumab does not make sense in the event of progression during immunotherapy maintenance and should only be used if immunotherapy has not yet been carried out.

6.1.2.1.4.6 NTRK alterations

Gene fusions involving the *NTRK genes* (*NTRK1*, *NTRK2*, *NTRK3*) have been identified as a very rare subgroup in a variety of malignant tumors, including biliary tract cancer, especially intrahepatic bile duct carcinomas. Individual patients with biliary tract cancer were treated in the pivotal studies for both larotrectinib and entrectinib [46, 47].

6.2 Treatment modalities

6.2.1 Resection

In principle, a distinction must be made between resections in the area of the liver or intra- and/or hepatic bile ducts and/or the pancreatic head due to the different localizations of biliary carcinomas [20, 54].

6.2.1.1 Resection of the intrahepatic bile ducts and liver

- Atypical resections/enucleations: these are based solely on the pathological findings without taking anatomical boundaries into account. For example, small superficial foci can be resected using wedge resections or marginal tumors can be resected using wedge resections to save parenchyma. The advantage of atypical resection is the minimal loss of functional liver parenchyma, so that this technique is used for small tumors and a previously damaged liver.
- Anatomical resections: Anatomical resections are the method of choice for liver malignancies in order to resect potential embolic spread of tumor cells into the associated segments. This refers to the complete removal of anatomically/functionally autonomous parenchymal districts that are supplied by an associated pedicle (branch of the V. portae, the hepatic artery and the D. hepaticus). A distinction is made between sector-oriented (right or left hemihepatectomy, left lateral and right posterior sectorectomy, central sectorectomy and right or left trisectorectomy) and segmental resections (mono-, bi- and polysegmentectomies, various combinations) [55].

6.2.1.2 Resection of the extrahepatic bile ducts and pancreatic head

Partial duodenopancreatectomy is the standard procedure for resectable carcinomas of the papilla or distal Ductus choledochus and pancreatic head.

The classic Kausch-Whipple operation and the Traverso-Longmire pylorus-preserving duodenopancreatectomy (PPPD) are available as surgical techniques. The en-bloc resection includes the pancreatic head together with the Ductus choledochus and the gallbladder, the duodenum with the proximal 5 cm of the jejunum as well as the peripancreatic lymph nodes, the duodenal ligament and the right side of the superior mesenteric artery and, in the case of the Kausch-Whipple operation, the distal stomach. An initial cholecystectomy is performed for functional reasons.

An extended lymphadenectomy (paraaortic or left side of the superior mesenteric artery) has no positive effect on overall survival, but increases morbidity.

Both surgical procedures are considered equivalent in terms of oncological radicality and thus the overall prognosis as well as postoperative mortality and morbidity.

The advantages of pylorus preservation and therefore PPPD are

- shortened operation time and convalescence

- fewer postoperative functional complaints such as dumping syndrome, diarrhea and dyspepsia.

In the case of large tumors with invasion of the pylorus or tumor-sparing lymph nodes in the area of the large or small gastric curvature (rare), a Kausch-Whipple operation is indicated; otherwise, pylorus-preserving surgery is preferred for functional outcome.

The following criteria indicating non-resectability should initially be checked by means of an exploratory laparotomy (which can be extended directly to definitive surgery if resectability is confirmed):

- Distant metastases, especially to the peritoneum and liver as well as paraaortic lymph node involvement
- Invasion of the mesenteric root
- Encasement the celiac trunk and/or the superior mesenteric artery.

Suspicious findings should be clarified by means of a histological frozen section examination. This does not apply to a biopsy of regional lymph nodes, as their involvement does not affect the surgical tactics/technique.

6.2.1.3 Liver transplantation

Liver transplantation is not a standard therapy [1]. A multidisciplinary concept according to the so-called *Mayo protocol* includes neoadjuvant radiochemotherapy (fluoropyrimidine-based) as a combination of external radiotherapy and internal brachytherapy before liver transplantation for perihilar tumors. For patients with unresectable UICC stage I and II Klatskin tumors, a 5-year survival rate of 82% and a complete remission rate of 42% (16/38 patients) was observed. However, only about 50% of the patients treated preoperatively could also be transplanted, with a significantly increased mortality [56].

With appropriate selection criteria (N0, cM0V0, tumor size < 3 cm, CA 19-9 < 1000 U/ml), comparable survival rates have been shown with liver transplantation alone, even without neoadjuvant therapy [57]. Data from randomized studies are still lacking, so that liver transplantation for biliary tract cancer is currently only possible in the context of studies in the Eurotransplant area.

In Germany, patients with a non-resectable Klatskin tumor (tumor extent < 3 cm, CA 19-9 <1000 U/ml, exclusion of lymph node and distant metastases) have the opportunity to participate in the pro-duct002 study (DRKS00013276).

6.2.1.4 Surgical resection of metastases

There is currently no evidence-based proof of benefit for the resection of metastases of biliary tract cancer. In individual cases, metastasectomy may be considered for oligometastasis.

6.2.2 Radiotherapy

There is insufficient evidence-based data available for the routine use of radiotherapy. Published data indicate a reduction of local recurrence rates after adjuvant radio(chemo)therapy alone, but the difference in survival remains unclear due to the lack of prospective randomized studies, see chapter 6.1.1.2.2.

A meta-analysis of more than 6000 patients from registries or predominantly single-arm studies (only one randomized study) showed a benefit for adjuvant radiochemotherapy or chemotherapy compared to radiotherapy alone, with patients with positive lymph node status (OR 0.49; $p = 0.004$) benefiting from adjuvant chemotherapy and patients after R1 resection benefiting from adjuvant radiochemotherapy (OR 0.36; $p = 0.002$) [29, 30].

In the single-arm SWOG-S0809 study, 79 evaluable patients with extrahepatic biliary carcinoma or gallbladder carcinoma after adjuvant chemotherapy with gemcitabine and capecitabine and subsequent radiochemotherapy with capecitabine showed a 2-year survival of 65% and a median overall survival of 35 months. Relevant grade 3 / 4 side effects were neutropenia, hand-foot syndrome and diarrhea [58].

A retrospective analysis of 63 patients showed an improvement in survival for R1 resected patients with perihilar biliary carcinoma. Here, adjuvant radiotherapy led to an improvement in 5-year survival of 33.9% compared to 13.5% after resection alone ($p = 0.0141$). However, other retrospective evaluations have shown inconsistent results with regard to the benefit from radiotherapy alone for extrahepatic perihilar biliary carcinoma [59].

In patients with locally advanced biliary tract cancer, a randomized phase II trial comparing chemotherapy (gemcitabine plus cisplatin) with radiochemotherapy (cisplatin + 5-FU) had to be discontinued due to poor recruitment. Overall, data could only be analyzed for 32 patients, which showed no additional benefit from radiochemotherapy [60]. Promising initial results are available for the use of precision radiotherapy [61].

Palliative radiotherapy can be used to control symptoms, e.g., in the case of bone metastases.

6.2.3 Interventional local therapy procedures

In analogy to HCC, local treatment methods can be used for non-resectable biliary tract cancer confined to the liver/bile ducts [62]. In principle, the following are available:

- Direct ablative procedures
 - Radiofrequency ablation (RFA)
 - Microwave ablation (MWA)
 - CT-guided high-dose-rate brachytherapy (CT-HDRBT): Method in which the radiation source is introduced directly into the affected tissue. Indications are tumors with a size > 3 cm as well as tumors near vessels or bile ducts (contraindications for RFA)
- Transarterial procedures
 - Transarterial chemoembolization (TACE)
 - Transarterial radioembolization/selective internal radiotherapy (TARE/SIRT)
 - Intra-arterial chemotherapy (HAI)
 - Chemosaturation

There is insufficient evidence-based data available for any of these procedures to implement them as standard procedures. The choice of method is based on the specific tumor location and overall situation as well as the expertise of the respective treating center.

Randomized clinical studies comparing these procedures with systemic tumor therapy are also not available. They should therefore generally be used as an adjunct to systemic therapy. The indication should be discussed in the multidisciplinary tumor conference, taking into account the overall therapy concept and potential toxicity.

In a retrospective analysis of 198 patients with intrahepatic biliary carcinoma who were treated with a local therapy procedure between 1992 and 2012, the following therapy procedures were used: transarterial chemoembolization (TACE) in 64.7%, drug-eluting beads (DEB) in 5.6%, pure embolization (TAE) in 6.6% and yttrium-90 SIRT in 23.2% of patients. Complete or partial remission was seen in 25.5%, 61.5% achieved disease stabilization with a median overall survival of 13.2 months with no relevant differences between the different treatment methods (TACE 13.4 months; DEB 10.5 months; TAE 14.3 months, SIRT 11.3 months; $p=0.46$). Patients with a complete or partial remission showed a positive impact on overall survival (according to mRECIST complete/partial remission HR 0.49; $p=0.001$). Serious grade 3 / 4 complications occurred in 16 (8%) of patients [63].

A meta-analysis of 224 patients treated with TARE/SIRT showed 1-, 2- and 3-year survival rates of 56%, 33% and 20% respectively. The best therapeutic results were shown for patients with a so-called "mass forming intrahepatic biliary carcinoma" (median survival 19.1 months versus 8.1 months for the infiltrative type; $p=0.002$) and for those who received TARE/SIRT as first-line therapy (median survival 24 months versus 11.5 months for pre-treated patients; $p=0.048$) and with concomitant chemotherapy (median survival 19.5 months versus 5.5 months for patients without concomitant chemotherapy; $p=0.042$) [64]. Similar results are available from a further retrospective pooled data analysis: here, the median survival of 298 patients treated was 15.5 months and the most common side effects were fatigue (33%), abdominal pain (28%) and nausea (25%). It is worth mentioning that in a subgroup analysis, 7/73 patients (10%) underwent secondary surgical resection [65].

Whenever possible, patients with locally advanced biliary tract cancer should be treated in trials.

6.2.4 Systemic tumor treatment

An overview of the various therapeutic options can be found in chapter 6.1.2.1.

6.2.4.1 Anticancer agents

6.2.4.1.1 Capecitabine

Capecitabine is an oral fluoropyrimidine that is metabolized in the body to 5-FU. In clinical comparative studies, it is at least as effective as 5-FU / folinic acid. It can be used instead of 5-FU in palliative therapy. Severe side effects (grade 3 / 4), which occurred in more than 5% of patients in the approval studies, are diarrhea and hand-foot syndrome.

Prior to fluoropyrimidine-containing chemotherapy, a mutation in the four most important dihydropyrimidine dehydrogenase (DPD) gene loci must be excluded in order to rule out a clinically relevant variant and thus deficiency (DPYD) [28] [https://www.dgho.de/publikationen/stellungnahmen/gute-aerztliche-praxis/dpd-testung/dpd-positionspapier-2020-konsens_logos_final]

6.2.4.1.2 Cisplatin

Platinum derivatives are among the most effective individual substances. In combination with other cytostatic drugs, cisplatin is part of the drug standard in palliative therapy. Specific severe side effects (grade 3 / 4) are nausea and vomiting, nephrotoxicity, polyneuropathy, ototoxicity, hematotoxicity and electrolyte imbalances and diarrhea.

6.2.4.1.3 Durvalumab

The PD-L1 inhibitor durvalumab showed good tolerability in combination with gemcitabine and cisplatin. Common side effects were anemia (48%), nausea (40%), constipation (32%) and neutropenia (32%). Grade 3 / 4 fatigue symptoms occur in approx. 3% of patients.

6.2.4.1.4 5-Fluorouracil

5-Fluorouracil is a fluoropyrimidine whose efficacy is increased by combining it with folinic acid. An alternative is oral therapy with capecitabine. Severe side effects include diarrhea and stomatitis. Patients with functionally relevant polymorphisms of the 5-FU degradation genes, especially dihydropyrimidine dehydrogenase (DPD) mutations, have an increased risk of severe side effects including neutropenia and neutropenic fever.

Prior to fluoropyrimidine-containing chemotherapy, a mutation in the four most important dihydropyrimidine dehydrogenase (DPD) gene loci must be excluded in order to rule out a clinically relevant variant and thus deficiency (DPYD) [28] [https://www.dgho.de/publikationen/stellungnahmen/gute-aerztliche-praxis/dpd-testung/dpd-positionspapier-2020-konsens_logos_final]

6.2.4.1.5 Futibatinib

Futibatinib is a next-generation FGFR 1-4 inhibitor and is used in FGFR2 fusions and rearrangements. The most common grade 3 / 4 adverse event in the pivotal study was hyperphosphatemia in approx. 30% of patients, the clinical relevance of which remains unclear and which generally does not require treatment. This also applies to an increase in ASAT in approx. 7%. Clinically relevant are stomatitis in approx. 6% and fatigue symptoms in approx. 6%.

6.2.4.1.6 Gemcitabine

Gemcitabine is a nucleoside analog. It is phosphorylated intracellularly and incorporated into the DNA instead of cytidine. Gemcitabine is effective in various solid tumors and hematological neoplasms. Severe side effects (grade 3 / 4), which occurred in more than 5% of patients in the large randomized phase 3 studies, are neutropenia (10-30%), thrombocytopenia (5-10%), fatigue (5-20%), anemia (5-10%), nausea / vomiting (5%) and laboratory hepatotoxicity with elevation of bilirubin and/or transaminases (5%). Gemcitabine is administered intravenously.

6.2.4.1.7 Irinotecan

Irinotecan is a topoisomerase I inhibitor. In second-line therapy, the remission rates in combination with 5-FU / folinic acid are 10-15%, the disease control rates (PR + SD) are up to 50%. In monotherapy, remission rates of up to 10% are described, and here too the disease control rates are higher. Progression-free survival and overall survival are significantly prolonged compared to fluoropyrimidine therapy. Severe side effects (grade 3 / 4), which occurred in more than 5% of patients in the pivotal studies, were diarrhea, nausea / vomiting, neutropenia and neutropenic fever. An alternative preparation is liposomal irinotecan.

Irinotecan is not approved for the treatment of biliary tract cancer (off-label indication).

6.2.4.1.8 Ivosidenib

Ivosidenib is a small molecule oral IDH1 inhibitor; a frequent side effect is the occurrence of ascites in up to 7% of patients.

6.2.4.1.9 Oxaliplatin

Oxaliplatin is a platinum derivative. It is highly effective in combination with fluoropyrimidines (5-FU/folinic acid, capecitabine). Severe side effects (grade 3 / 4), which occurred in more than 5% of patients in the pivotal studies, were nausea/vomiting, diarrhea, mucositis and polyneuropathy. Of particular clinical relevance is the occurrence of polyneuropathy, which limits the duration of therapy. The intravenous administration of calcium and magnesium cannot reduce the risk of polyneuropathy.

6.2.4.1.10 Pembrolizumab

Pembrolizumab is an immune checkpoint inhibitor. It is a fully humanized monoclonal antibody of the immunoglobulin G4 (IgG4) class that binds to the PD1 receptor on T cells and prevents interaction with the PD1 receptor ligand that actually binds here. In this way, the cellular immune system is indirectly stimulated by suppressing the inhibitory influence of the PD1 ligand/PD1 receptor interaction. Pembrolizumab is approved for biliary tract cancer in combination with chemotherapy in first-line therapy for "all comers" and as monotherapy for the treatment of MSI-H or with a dMMR after at least one prior therapy

6.2.4.1.11 Pemigatinib

Pemigatinib is an oral FGFR2 inhibitor for FGFR2 fusions and rearrangements. The most common side effect - usually of little clinical relevance - is hypophosphatemia (60%). Severe side effects (grade 3 / 4) are hypophosphatemia (12%), arthralgia (6%), stomatitis (5%), hyponatremia (5%), abdominal pain (5%) and fatigue (5%).

6.3 Special treatment settings

6.3.1 Carcinomas of the Ampulla Vateri

6.3.1.1 Nomenclature

Carcinomas of the Ampulla Vateri are a rare family of entities and are listed as a subgroup of tumors of the small intestine and ampulla in the latest WHO classification.

Ampullary adenocarcinomas are by far the most common; other types of carcinomas (neuroendocrine, others, see below) are extremely rare in this localization. The ampullary carcinomas are divided into

- (Peri)ampullary duodenal adenocarcinomas, often associated with adenomatous precursors
- Adenocarcinomas of ductal ampullary origin

- Intraampullary adenocarcinomas on the basis of an intraampullary papillary/tubular neoplasia
- Adenocarcinomas NOS for which an exact assignment to one of the three families mentioned is not possible

These tumors must be differentiated from duodenal carcinomas, distal bile duct carcinomas and pancreatic carcinomas that also affect the papilla region. The distinction is sometimes blurred and is then determined by the punctum maximum of the tumor manifestation. The differentiation of carcinomas of the Ampulla Vateri from the aforementioned carcinomas is important in principle due to a better prognosis and different treatment methods. This is also reflected in a separate TNM classification (C24.1, carcinoma of the Ampulla Vateri), see chapter [5.3.2.5](#).

In patients with familial adenomatous polyposis coli (FAP), adenomas also occur in the duodenum or ampulla in 50-90% of patients. The risk of malignant degeneration is increased up to 200-fold compared to the normal population, and the lifetime risk of developing periampullary carcinoma in people with FAP is 12% [66].

6.3.1.2 Diagnostics in carcinomas of the Ampulla Vateri

Diagnosis is usually made at a previous stage due to the clinical symptoms (jaundice/cholestasis), with approx. 50% of patients in a resectable stage at diagnosis [67, 68].

The tumor entity is determined histologically, usually on the basis of bioptic confirmation of the tumor. For the differential diagnosis between pancreaticobiliary and intestinal subtypes in the predominant group of adenocarcinomas of the Ampulla Vateri, additional immunohistologic examinations are often used in addition to conventional histology (intestinal growth form and cell image versus pancreaticobiliary growth form and cell image). The gastric subtype (with gastric-like mucin production), which is sometimes also classified separately, is closely related to the pancreatobiliary type and is therefore often classified in this subgroup, which is also followed by the current WHO classification.

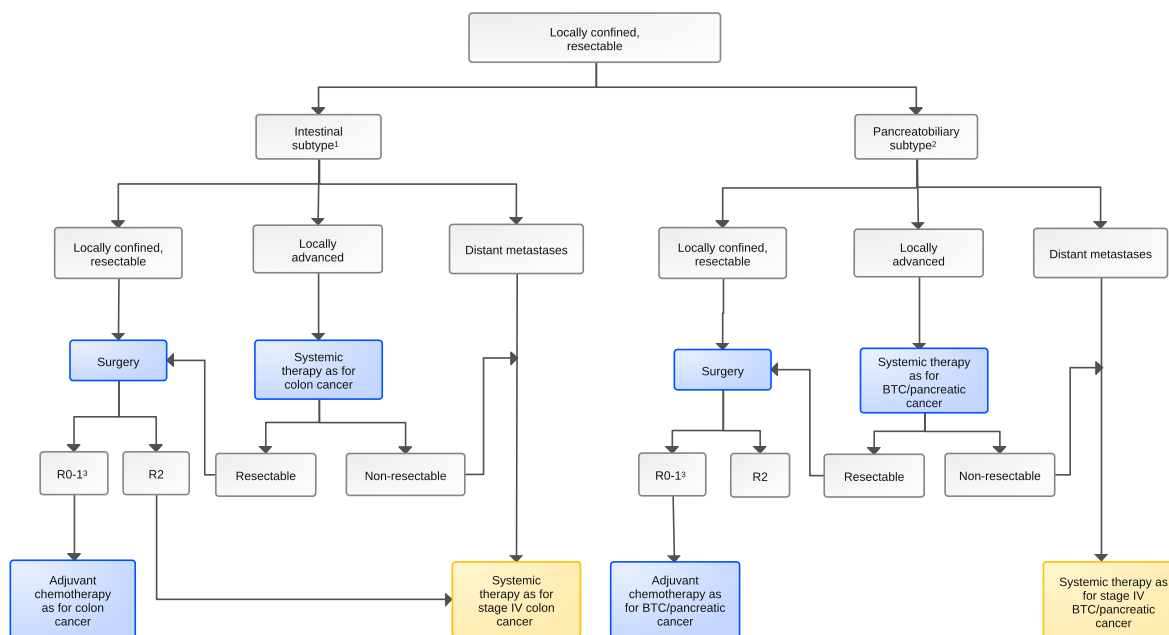
Typically, immunohistochemical detection of mucin-2 (MUC2) and caudal homeobox gene transcription factor-2 (CDX2) as well as cytokeratin 20 is indicative of the intestinal type, while the expression of mucin-1 (MUC1), mucin-5AC (MUC5AC) and cytokeratin 7 is indicative of the pancreatobiliary subtype [69, 70]. Mixed intestinal-pancreatobiliary types are common (>30% of tumors). In addition, the very rare mucinous, poorly cohesive, medullary, adenosquamous, neuroendocrine and undifferentiated (sometimes with osteoclast giant cells or rhabdoid phenotype) carcinomas of the ampullary region are differentiated. Mixed forms occur.

Predictive morphomolecular factors have not been established for this family of entities in routine diagnostics.

6.3.1.3 Therapy of carcinoma of the Ampulla Vateri

[Figure 8](#) provides a treatment algorithm.

Figure 8: Algorithm for the treatment of Ampulla Vateri carcinomas



Legend:

■ curative intended therapy; ■ non-curative intended therapy;

¹ CDX2 positive, MUC2 positive

² CDX2 negative, MUC1 positive

³ R - Classification of the condition after surgical resection of the primary tumor

T1 carcinomas <1 cm have only a minimal risk of metastasis, so that local resection may be sufficient.

For resectable tumors ≥ 1 cm, pancreaticoduodenectomy is the method of choice; for information on the various surgical procedures, see Treatment modalities – Surgical resection, chapter 6.2.1 [66].

Data from the ESPAC-3 "periampullary cancer" study (difference 8 months, $p=0.25$) [71] and the CONKO-001 study [72] indicate an improvement in survival with adjuvant chemotherapy with gemcitabine. Supplementary radiotherapy does not lead to any improvement in survival (ESPAC-1) [73].

A choice of adjuvant therapy according to the histological subtype appears to make sense, so that carcinomas of the intestinal subtype (CDX2 positive) should be treated in analogy to adjuvant therapy for colon cancer and carcinomas of the pancreaticobiliary subtype (MUC1 positive) in analogy to therapy for biliary tract cancer or pancreatic carcinoma.

In the case of inoperable locally advanced and/or metastatic tumors, systemic therapy is the first priority; this is palliative and can be supplemented by local measures if necessary.

5% ($n=20$) of the patients in the ABC-02 study had a periampullary carcinoma ("ampullary cancer") [32]. Palliative chemotherapy with gemcitabine and cisplatin also showed a significant improvement in survival in these patients (see Systemic tumor therapy, chapter 6.1.2.1.1) Data from a subgroup analysis of a randomized phase III trial are thus available, but no information on the respective histological subtypes.

In principle, the choice of chemotherapy for advanced inoperable carcinomas of the Ampulla Vateri should also be based on the histologic subtype, so that carcinomas of the intestinal subtype (CDX2 positive) should be treated in analogy to colorectal cancer (see Onkopedia guideline Colon cancer) and carcinomas of the pancreaticobiliary subtype (CDX2 negative, MUC1 positive) can be treated in analogy to biliary carcinomas (see Figure 8 of this LL) or pancreatic carcinoma (see Onkopedia guideline Pancreatic cancer).

6.3.2 Symptomatic cholestasis

Clinically relevant cholestasis occurs during the course of the disease in up to 50% of patients with advanced biliary carcinoma, particularly with extrahepatic localization. In addition to improving obstructive jaundice, the restoration of bile outflow serves to stabilize liver function, prevent cholangitis and thus maintain or improve quality of life.

Technically, endoscopic retrograde cholangiography (ERC) with stent implantation or percutaneous transhepatic cholangiodrainage (PTCD) are available. The insertion of a Yamakawa drain may be useful for permanent internal bile drainage using a percutaneous catheter. In patients with recurrent stent occlusion and a life expectancy of > 3 months, the implantation of self-expanding and fully covered metal stents (SEMS) should be considered if the leading tumor stenosis is located in the choledochal duct.

In addition, interventional procedures such as intraluminal RFA [74] or brachytherapy [75] can be added in specialized centers to improve the open rate of the stents or drainage.

The benefits of photodynamic therapy remain unclear despite a large number of smaller and generally retrospective studies. In this procedure, photosensitizing substances are applied which accumulate in the tumor tissue and lead to tissue destruction through radical formation. The disadvantage is the low penetration depth and general phototoxicity, which makes it necessary to avoid exposure to light. A recent meta-analysis [76] of 402 patients showed a benefit in terms of survival and stent openness rates compared to stent therapy alone. Data from randomized studies, particularly in the case of concurrent systemic chemotherapy, are still lacking.

7 Rehabilitation

The tumor disease itself and the necessary therapies - both surgical and systemic - sometimes lead to considerable secondary disorders such as weight loss, maldigestion, neuropathy and reduced exercise tolerance. This is often accompanied by restrictions due to tumor- and/or surgery-related chronic cholestasis and the need for permanent drainage. Many patients are also mentally impaired and suffer from fatigue syndrome.

Targeted rehabilitative measures are therefore necessary. These should be carried out as soon as possible after completion of primary therapy. When selecting a rehabilitation facility, approval of the institution for patients with tumor diseases by the health insurance (pension insurance, health insurance) is a mandatory prerequisite; in addition, the patient's right to choose should be taken into account in accordance with §9 German SGB IX.

During rehabilitation, comprehensive nutritional advice should be given, patients should be included in the training kitchen, and it should be possible to administer all scientifically recognized diets, from normal whole foods to complete parenteral nutrition. All patients should be offered psycho-oncological care. Rehabilitation facilities should be able to continue systemic tumor therapies if indicated.

Patients who have not yet reached the statutory retirement age should be informed about benefits for participation in working life as part of medical-occupational rehabilitation (MBOR).

8 Monitoring and follow-up

8.1 Monitoring for disease progression

During ongoing chemotherapy, the patient's general condition and bodily and organ functions should generally be checked every 1-2 weeks. Laboratory blood count, liver and kidney values

and, depending on the clinical symptoms, other parameters should be determined. Image morphological follow-up examinations are also regularly indicated in order to recognize negative developments of the disease in good time and to avoid exposing patients to ineffective therapies for an unnecessarily long time or to open up the chance of more effective therapies.

8.2 Follow-up

There are no prospective data on the basis of which a specific follow-up regimen can be recommended. In past and ongoing studies, the regimen in Table 14 has become established, see also ESMO guideline 2023 [2]:

Table 14: Structured monitoring and follow-up for curative therapy

Procedure	Months after completion of therapy													
	3	6	9	12	15	18	21	24	30	36	42	48	54	60
Physical examination	X	X	X	X	X	X	X	X	X	X	X	X	X	X
Laboratory: Liver function parameters, LDH, CA 19-9, CEA	X	X	X	X	X	X	X	X	X	X	X	X	X	X
Imaging: Abdominal sonography and/or CT thorax/abdomen/pelvis and/or MRI abdomen	X	X	X	X	X	X	X	X	X	X	X	X	X	X

9 References

- Rizvi S, Gores GJ. Pathogenesis, diagnosis, and management of cholangiocarcinoma. *Gastroenterology* 2013;145:1215-1229. DOI:10.1053/j.gastro.2013.10.013
- Vogel A, Bridgewater J, Edeline J et al. Biliary tract cancer: ESMO Clinical Practice Guideline for diagnosis, treatment and follow-up. *Ann Oncol* 2023;34:127-140. DOI:10.1016/j.annonc.2022.10.506.
- Hundal R, Shaffer EA. Gallbladder cancer: epidemiology and outcome. *Clin Epidemiol* 2014;6:99-109. DOI:10.2147/CLEP.S37357
- Gesellschaft der epidemiologischen Krebsregister in Deutschland e.V., Sonderauswertung Datengrundlage Mortalität: Todesursachenstatistik, <https://www.destatis.de/de/methoden/qualitaet/qualitaetsberichte/gesundheit/todesursachen>
- Robert Koch Institute (ed.) and the Society of Epidemiological Cancer Registries in Germany (ed.) *Cancer in Germany 2013-2014*, 11th edition 2017; 40-47, 2017. https://www.krebsdaten.de/krebs/de/content/publikationen/krebs_in_deutschland/kid_2017/krebs_in_deutschland_2017
- Society of Epidemiological Cancer Registries in Germany e.V., www.gbe-bund.de
- https://www.tumorregister-muenchen.de/facts/specific_analysis.php
- Joinpoint Regression Program, Version 4.9.0.0 - March 2021; Statistical Methodology and Applications Branch, Surveillance Research Program, National Cancer Institute. <https://surveillance.cancer.gov/joinpoint/>
- Razumilava N, Gores GJ. Cholangiocarcinoma. *Lancet* 2014;383:2168-2179. DOI:10.1016/S0140-6736(13)61903-0
- Blechacz B. Cholangiocarcinoma: Current knowledge and new developments. *Gut Liver* 2017;11:13-26. DOI:10.5009/gnl15568
- Shukla SK, Singh G, Shahi KS et al. Staging, treatment and future approaches of gallbladder carcinoma. *J Gastrointest Cancer* 2018;49:9-15. DOI:10.1007/s12029-017-0036-5

12. McCain RS, Diamond A, Jones C, Coleman HG. Current practices and future prospects for the management of gallbladder polyps: A topical review. *World J Gastroenterol* 2018;24:2844-2852. DOI:10.3748/wjg.v24.i26.2844
13. Ghouri YA, Mian I, Blechacz B. Cancer review: Cholangiocarcinoma. *J Carcinog* 2015;14:1. DOI:10.4103/1477-3163.151940
14. Wernberg JA, Lucarelli DD. Gallbladder cancer. *Surg Clin North Am* 2014;94:343-336. DOI:10.1016/j.suc.2014.01.009
15. Isayama H, Tazuma S, Kokudo N et al. Clinical guidelines for primary sclerosing cholangitis 2017. *J Gastroenterol* 2018;53:1006-1034. DOI:10.1007/s00535-018-1484-9
16. AWMF S3 guideline: Diagnosis and treatment of hepatocellular carcinoma and biliary carcinoma, version 4.0, August 2023. https://register.awmf.org/assets/guidelines/032-053olk_s3_diagnostik-therapie-hepatozellulaere-karzinom-biliaere-karzinome_2023-08
17. TNM: Classification of Malignant Tumors, 8th edition [Internet]. Wiley.com. Available at: <https://www.wiley-vch.de/de/fachgebiete/medizin-und-gesundheit/tnm-klassifikation-maligner-tumoren-978-3-527-34280-8>
18. Jarnagin WR, Fong Y, DeMatteo RP et al. Staging, resectability, and outcome in 225 patients with hilar cholangiocarcinoma. *Ann Surg* 2001;234:507-517. PMID:11573044
19. Chang DK, Jamieson NB, Johns AL et al. Histomolecular phenotypes and outcome in adenocarcinoma of the ampulla of Vater. *J Clin Oncol* 2013;31:1348-1356. DOI:10.1200/JCO.2012.46.8868
20. Birth M, Ittel TH, Pereira PL (eds.). *Hepatobiliary and pancreatic tumors - Interdisciplinary approach*. Springer-Verlag Berlin Heidelberg 2010. DOI:10.1007/978-3-642-04935-4
21. Goetze TO, Paolucci V. Adequate extent in radical re-resection of incidental gallbladder carcinoma: analysis of the German Registry. *Surg Endosc* 2010;24:2156-2164. DOI:10.1007/s00464-010-0914-4
22. Levi Sandri GB, Spoletini G, Mascianà G et al. The role of minimally invasive surgery in the treatment of cholangiocarcinoma. *Eur J Surg Oncol* 2017;43:1617-1621. DOI:10.1016/j.ejso.2017.02.012
23. Horgan AM, Amir E, Walter T, Knox JJ. Adjuvant therapy in the treatment of biliary tract cancer: a systematic review and meta-analysis. *J Clin Oncol* 2012;30:1934-1940. DOI:10.1200/JCO.2011.40.5381
24. Wang ML, Ke ZY, Yin S, Liu CH, Huang Q. The effect of adjuvant chemotherapy in resectable cholangiocarcinoma: A meta-analysis and systematic review. *Hepatobiliary Pancreat Dis Int* 2019;18:110-116. DOI:10.1016/j.hbpd.2018.11.001
25. Primrose JN, Fox RP, Palmer DH et al. Capecitabine compared with observation in resected biliary tract cancer (BILCAP): a randomized, controlled, multicentre, phase 3 study. *Lancet Oncol* 2019;20:663-673. DOI:10.1016/S1470-2045(18)30915-X
26. Edeline J, Benabdelghani M, Bertaut A et al. Gemcitabine and oxaliplatin chemotherapy or surveillance in resected biliary tract cancer (PRODIGE 12-ACCORD 18-UNICANCER GI): a randomized phase III study. *J Clin Oncol* 2019;37:658-667. DOI:10.1200/JCO.18.00050
27. Ebata T, Hirano S, Konishi M et al. Randomized clinical trial of adjuvant gemcitabine chemotherapy versus observation in resected bile duct cancer. *Br J Surg* 2018;105:192-202. DOI:10.1002/bjs.10776
28. Wörmann B, Bokemeyer C, Burmeister T et al: Dihydropyrimidine dehydrogenase testing prior to treatment with 5-fluorouracil, capecitabine, and tegafur: a consensus paper. *Oncol Res Treat* 2020;43:628-636, 2020. DOI:10.1159/000510258

29. Kim BH, Kwon J, Chie EK et al. Adjuvant chemoradiotherapy is associated with improved survival for patients with resected gallbladder carcinoma: a systematic review and meta-analysis. *Ann Surg Oncol* 2018;25:255-264. DOI:10.1245/s10434-017-6139-1
30. Shi YQ, Zhang JY, Tian H et al. Role of adjuvant (chemo)radiotherapy for resected extrahepatic cholangiocarcinoma: a meta-analysis. *J Zhejiang Univ Sci B* 2020;21:549-559. DOI:10.1631/jzus.B1900691
31. Le Roy B, Gelli M, Pittau G et al. Neoadjuvant chemotherapy for initially unresectable intrahepatic cholangiocarcinoma. *Br J Surg* 2019;105:839-847. DOI:10.1002/bjs.10641
32. Valle J, Wasan H, Palmer DH et al. Cisplatin plus gemcitabine versus gemcitabine for biliary tract cancer. *N Engl J Med* 2010;362:1273-1281. DOI:10.1056/NEJMoa0908721
33. Okusaka T, Nakachi K, Fukutomi A et al. Gemcitabine alone or in combination with cisplatin in patients with biliary tract cancer: a comparative multicenter study in Japan. *Br J Cancer* 2010;103:469-474. DOI:10.1038/sj.bjc.6605779
34. Lamarca A, Palmer DH, Wasan HS et al. Second-line FOLFOX chemotherapy versus active symptom control for advanced biliary tract cancer (ABC-06): a phase 3, open-label, randomized, controlled trial. *Lancet Oncol* 2021;22:609-701. DOI:10.1016/S1470-2045(21)00027-9
35. Brieau B, Dahan L, Rycke YD et al. Second-line chemotherapy for advanced biliary tract cancer after failure of the gemcitabine-platinum combination: A large multicenter study by the Association des Gastro-Entérologues Oncologues. *Cancer* 2015;121:3290-3297. DOI:10.1002/cncr.29471
36. Zheng Y, Tu X, Zhao P et al. A randomized phase II study of second-line XELIRI regimen versus irinotecan monotherapy in advanced biliary tract cancer patients progressed on gemcitabine and cisplatin. *Br J Cancer* 2018;119:291-295. DOI:10.1038/s41416-018-0138-2
37. Yoo C, Kim KP, Jeong JH et al. Liposomal irinotecan plus fluorouracil and leucovorin versus fluorouracil and leucovorin for metastatic biliary tract cancer after progression on gemcitabine plus cisplatin (NIFTY): a multicentre, open-label, randomized, phase 2b study. *Lancet Oncol* 2021;22:1560-1572. DOI:10.1016/S1470-2045(21)00486-1
38. Ramaswamy A, Ostwal V, Sharma A et al. Efficacy of capecitabine plus irinotecan vs irinotecan monotherapy as second-line treatment in patients with advanced gallbladder cancer: a multicenter phase 2 randomized clinical trial (GB-SELECT). *JAMA Oncol* 2021;7:436-439. DOI:10.1001/jamaoncol.2020.6166
39. Lamarca A, Hubner RA, David Ryder W, Valle JW. Second-line chemotherapy in advanced biliary cancer: a systematic review. *Ann Oncol* 2014;25:2328-2338. DOI:10.1093/annonc/mdu162
40. Walter T, Horgan AM, McNamara M et al. Feasibility and benefits of second-line chemotherapy in advanced biliary tract cancer: a large retrospective study. *Eur J Cancer* 2013;49:329-335. DOI:10.1016/j.ejca.2012.08.003
41. Neuzillet C, Casadei Gardini A, Brieau B et al. Prediction of survival with second-line therapy in biliary tract cancer: Actualization of the AGEO CT2BIL cohort and European multicentre validations. *Eur J Cancer* 2019;111:94-106. DOI:10.1016/j.ejca.2019.01.019
42. Verlingue L, Malka D, Allorant A et al. Precision medicine for patients with advanced biliary tract cancers: An effective strategy within the prospective MOSCATO-01 trial. *Eur J Cancer* 2017;87:122-130. DOI:10.1016/j.ejca.2017.10.013
43. Abou-Alfa GK, Sahai V, Hollebecque A et al. Pemigatinib for previously treated, locally advanced or metastatic cholangiocarcinoma: a multicenter, open-label, phase 2 study. *Lancet Oncol* 2020;21:671-684. DOI:10.1016/S1470-2045(20)30109-1

44. Javle M, Lowery M, Shroff RT et al. Phase II study of BGJ398 in patients with FGFR-altered advanced cholangiocarcinoma. *J Clin Oncol* 2016;36:276-282. DOI:10.1200/JCO.2017.75.5009
45. Javle M, Roychowdhury S, Kelley RK et al. Infigratinib (BGJ398) in previously treated patients with advanced or metastatic cholangiocarcinoma with FGFR2 fusions or rearrangements: mature results from a multicentre, open-label, single-arm, phase 2 study. *Lancet Gastroenterol Hepatol* 2021;6:803-815. DOI:10.1016/S2468-1253(21)00196-5
46. Drilon A, Laetsch TW, Kummar S et al. Efficacy of larotrectinib in TRK fusion-positive cancers in adults and children. *N Engl J Med* 2018;378:731-739. DOI:10.1056/NEJMoa1714448
47. Doebele RC, Drilon A, Paz-Ares L et al. Entrectinib in patients with advanced or metastatic NTRK fusion-positive solid tumors: integrated analysis of three phase 1-2 trials. *Lancet Oncol* 2020;21:271-282. DOI:10.1016/S1470-2045(19)30691-6
48. Abou-Alfa GK, Macarulla T, Javle MM et al. Ivosidenib in IDH1-mutant, chemotherapy-refractory cholangiocarcinoma (ClarIDHy): a multicentre, randomized, double-blind, placebo-controlled, phase 3 study. *Lancet Oncol* 2020;21:796-807. DOI:10.1016/S1470-2045(20)30157-1
49. Subbiah V, Lassen U, Élez E et al. Dabrafenib plus trametinib in patients with BRAFV600E-mutated biliary tract cancer (ROAR): a phase 2, open-label, single-arm, multicenter basket trial. *Lancet Oncol* 2020;21:1234-1243. DOI:10.1016/S1470-2045(20)30321-1
50. Javle M, Borad MJ, Azad NS et al. Pertuzumab and trastuzumab for HER2-positive, metastatic biliary tract cancer (MyPathway): a multicentre, open-label, phase 2a, multiple basket study. *Lancet Oncol* 2021;22:1290-1300. DOI:10.1016/S1470-2045(21)00336-3
51. Le DT, Durham JN, Smith KN et al. Mismatch repair deficiency predicts response of solid tumors to PD-1 blockade. *Science* 2017;357:409-413. DOI:10.1126/science.aan6733
52. Kim RD, Chung V, Alese OB et al. A phase 2 multi-institutional study of nivolumab for patients with advanced refractory biliary tract cancer. *JAMA Oncol*. 2020;6:888-894. DOI:10.1001/jamaoncol.2020.0930
53. Piha-Paul SA, Oh DY, Ueno M et al. Efficacy and safety of pembrolizumab for the treatment of advanced biliary cancer: Results from the KEYNOTE-158 and KEYNOTE-028 studies. *Int J Cancer* 2020;147:2190-2198. DOI:10.1002/ijc.33013
54. Seyama Y, Makuuchi M. Current surgical treatment for bile duct cancer. *World J Gastroenterol* 2007;13:1505-1515. DOI:10.3748/wjg.v13.i10.1505
55. Scheele J. Anatomical und atypical Leberresektionen [Anatomical and atypical liver resections]. *Chirurg* 2001;72:113-124. DOI:10.1007/s001040051278
56. Heimbach JK, Gores GJ, Haddock MG et al. Liver transplantation for unresectable perihilar cholangiocarcinoma. *Semin Liver Dis* 2004;24:201-207. DOI:10.1055/s-2004-828896
57. Mantel HTJ, Westerkamp AC, Adam R et al. Strict selection alone of patients undergoing liver transplantation for hilar cholangiocarcinoma is associated with improved survival. *PLoS ONE* 2016;11:e0156127. DOI:10.1371/journal.pone.0156127
58. Ben-Josef E, Guthrie KA, El-Khoueiry AB et al. SWOG S0809: a phase II intergroup trial of adjuvant capecitabine and gemcitabine followed by radiotherapy and concurrent capecitabine in extrahepatic cholangiocarcinoma and gallbladder carcinoma. *J Clin Oncol* 2015;33:2617-2622. DOI:10.1200/JCO.2014.60.2219
59. Poruk KE, Pawlik TM, Weiss MJ. Perioperative management of hilar cholangiocarcinoma. *J Gastrointest Surg* 2015;19:1889-1899. DOI:10.1007/s11605-015-2854-8

60. Phelip JM, Vendrely V, Rostain F et al. Gemcitabine plus cisplatin versus chemoradiotherapy in locally advanced biliary tract cancer: Fédération Francophone de Cancérologie Digestive 9902 phase II randomized study. *Eur J Cancer* 2014;50:2975-2982. DOI:10.1016/j.ejca.2014.08.013
61. Fuller CD, Dang ND, Wang SJ et al. Image-guided intensity-modulated radiotherapy (IG-IMRT) for biliary adenocarcinomas: initial clinical results. *Radiother Oncol* 2009;92:249-254. DOI:10.1016/j.radonc.2009.02.015
62. Labib PL, Davidson BR, Sharma RA, Pereira SP. Locoregional therapies in cholangiocarcinoma. *Hepat Oncol* 2017;4:99-109. DOI:10.2217/hep-2017-0014
63. Hyder O, Marsh JW, Salem R et al. Intra-arterial therapy for advanced intrahepatic cholangiocarcinoma: a multi-institutional analysis. *Ann Surg Oncol* 2013;20:3779-3786. DOI:10.1245/s10434-013-3127-y
64. Cucchetti A, Cappelli A, Mosconi C et al. Improving patient selection for selective internal radiation therapy of intra-hepatic cholangiocarcinoma: A meta-regression study. *Liver Int* 2017;37:1056-1064. DOI:10.1111/liv.13382
65. Al-Adra DP, Gill RS, Axford SJ et al. Treatment of unresectable intrahepatic cholangiocarcinoma with yttrium-90 radioembolization: a systematic review and pooled analysis. *Eur J Surg Oncol* 2015;41:120-127. DOI:10.1016/j.ejso.2014.09.007
66. Neuhaus PJ, Wittekind CF. Classification of malignant tumors of the gastrointestinal tract II. Springer Verlag Berlin Heidelberg 2007. DOI:10.1007/978-3-540-49821-6
67. Riall TS, Cameron JL, Lillemoe KD et al. Resected periampullary adenocarcinoma: 5-year survivors and their 6- to 10-year follow-up. *Surgery* 2006;140:764-772. DOI:10.1016/j.surg.2006.04.006
68. Ahn DH, Bekaii-Saab T. Ampullary cancer: an overview. *Am Soc Clin Oncol Educ Book* 2014:112-115. DOI:10.14694/EdBook_AM.2014.34.112
69. Kohler I, Jacob D, Budzies J et al. Phenotypic and genotypic characterization of carcinomas of the papilla of Vater has prognostic and putative therapeutic implications. *Am J Clin Pathol* 2011;135:202-211. DOI:10.1309/AJCPCTCUQSYI89YT
70. Perysinakis I, Minaidou E, Leontara V et al. Differential expression of β -catenin, EGFR, CK7, CK20, MUC1, MUC2, and CDX2 in intestinal and pancreatobiliary-type ampullary carcinomas. *Int J Surg Pathol* 2017;25:31-40. DOI:10.1177/1066896916664987
71. Neoptolemos JP, Moore MJ, Cox TF et al. Effect of adjuvant chemotherapy with fluorouracil plus folinic acid or gemcitabine vs observation on survival in patients with resected periampullary adenocarcinoma: the ESPAC-3 periampullary cancer randomized trial. *JAMA* 2012;308:147-156. DOI:10.1001/jama.2012.7352
72. Oettle H, Neuhaus P, Hochhaus A et al. Adjuvant chemotherapy with gemcitabine and long-term outcomes among patients with resected pancreatic cancer: the CONKO-001 randomized trial. *JAMA* 2013;310:1473-1481. DOI:10.1001/jama.2013.279201
73. Neoptolemos JP, Dunn JA, Stocken DD et al. Adjuvant chemoradiotherapy and chemotherapy in resectable pancreatic cancer: a randomized controlled trial. *Lancet* 2001;358:1576-1585. PMID:11716884
74. Sofi AA, Khan MA, Das A et al. Radiofrequency ablation combined with biliary stent placement versus stent placement alone for malignant biliary strictures: a systematic review and meta-analysis. *Gastrointest Endosc* 2018;87:944-951. DOI:10.1016/j.gie.2017.10.029
75. Xu X, Li J, Wu J et al. A systematic review and meta-analysis of intraluminal brachytherapy versus stent alone in the treatment of malignant obstructive jaundice. *Cardiovasc Intervent Radiol* 2018;41:206-217. DOI:10.1007/s00270-017-1827-6

76. Moole H, Tathireddy H, Dharmapuri S et al. Success of photodynamic therapy in palliating patients with nonresectable cholangiocarcinoma: A systematic review and meta-analysis. *World J Gastroenterol* 2017;23:1278-1288. DOI:10.3748/wjg.v23.i7.1278
77. Goeppert B, Stichel D, Toth R et al Integrative analysis reveals early and distinct genetic and epigenetic changes in intraductal papillary and tubulopapillary cholangiocarcinogenesis. *Gut* 2022;71:391-401. DOI:10.1136/gutjnl-2020-322983
78. Goyal L, Meric-Bernstam F, Hollebecque A et al. Futibatinib for FGFR2-rearranged intrahepatic cholangiocarcinoma. *N Engl J Med* 2023;388:228-239. DOI:10.1056/NEJMoa2206834
79. Gross C, Engleitner T, Lange S et al. Whole exome sequencing of biliary tubulopapillary neoplasms reveals common mutations in chromatin remodeling genes. *Cancers (Basel)* 2021;13:2742. DOI:10.3390/cancers13112742
80. Harding JJ, Fan J, Oh DY et al. Zanidatamab for HER2-amplified, unresectable, locally advanced or metastatic biliary tract cancer (HERIZON-BTC-01): a multicentre, single-arm, phase 2b study. *Lancet Oncol* 2023;24:772-782. DOI:10.1016/S1470-2045(23)00242-5
81. Harding JJ, Piha-Paul SA, Shah RH et al. Antitumor activity of neratinib in patients with HER2-mutant advanced biliary tract cancers. *Nat Commun* 2023;14:630. DOI:10.1038/s41467-023-36399-y
82. Ioka T, Kanai M, Kobayashi S et al. Randomized phase III study of gemcitabine, cisplatin plus S-1 versus gemcitabine, cisplatin for advanced biliary tract cancer (KHBO1401-MIT-SUBA). *J Hepatobiliary Pancreat Sci* 2023;30:102-110. DOI:10.1002/jhbp.1219
83. Kelley RK, Ueno M, Yoo C et al. Pembrolizumab in combination with gemcitabine and cisplatin compared with gemcitabine and cisplatin alone for patients with advanced biliary tract cancer (KEYNOTE-966): a randomized, double-blind, placebo-controlled, phase 3 trial. *Lancet* 2023;401:1853-1865. DOI:10.1016/S0140-6736(23)00727-4
84. Kendre G, Murugesan K, Brummer T, Segatto O, Saborowski A, Vogel A. Charting co-mutation patterns associated with actionable drivers in intrahepatic cholangiocarcinoma. *J Hepatol* 2023;78:614-626. DOI:10.1016/j.jhep.2022.11.030
85. Nakamura Y, Mizuno N, Sunakawa Y et al. Tucatinib and trastuzumab for previously treated human epidermal growth factor receptor 2-positive metastatic biliary tract cancer (SGNTUC-019): A phase II basket study. *J Clin Oncol* 2023;41:5569-5578. DOI:10.1200/JCO.23.00606M_
86. Oh DY, He AR, Qin S et al, Durvalumab plus Gemcitabine and Cisplatin in Advanced Biliary Tract Cancer, *NEJM Evid* 2022;1(8) DOI:10.1056/EVIDoa2200015
87. Ohba A, Morizane C, Kawamoto Y et al. Trastuzumab deruxtecan (T-DXd; DS-8201) in patients (pts) with HER2-expressing unresectable or recurrent biliary tract cancer (BTC): An investigator-initiated multicenter phase 2 study (HERB trial). *J Clin Oncol* 40, 2022 (suppl 16; abstr 4006). DOI:10.1200/JCO.2022.40.16_suppl.4006
88. Phelip JM, Desrame J, Edeline J et al. Modified FOLFIRINOX versus CISGEM chemotherapy for patients with advanced biliary tract cancer (PRODIGE 38 AMEBICA): a randomized phase II study. *J Clin Oncol* 2022;40:262-271. DOI:10.1200/JCO.21.00679
89. Sharma A, Kalyan Mohanti B et al. Modified gemcitabine and oxaliplatin or gemcitabine + cisplatin in unresectable gallbladder cancer: Results of a phase III randomized controlled trial. *Eur J Cancer* 2019;123:162-170. DOI:10.1016/j.ejca.2019.10.004
90. Shroff RT, Guthrie KA, Scott AJ et al. SWOG 1815: A phase III randomized trial of gemcitabine, cisplatin, and nab-paclitaxel versus gemcitabine and cisplatin in newly diagnosed, advanced biliary tract cancers. *J Clin Oncol* 2023; 41 (suppl 4; abstr LBA490) DOI:10.1200/JCO.2023.41.4_suppl.LBA490

91. Singhi AD, Wood LD, Parks E et al. Recurrent rearrangements in PRKACA and PRKACB in intraductal oncocytic papillary neoplasms of the pancreas and bile duct. *Gastroenterology* 2020;158:573-582. DOI:10.1053/j.gastro.2019.10.028
92. Vogel A, Wenzel P, Folprecht G et al. Nal-IRI and 5-FU/LV compared to 5-FU/LV in patients with cholangio- and gallbladder carcinoma previously treated with gemcitabine-based therapies (NALIRICC - AIO-HEP- 0116). *Ann Oncol* 2022;33(S7):S563-S564. DOI:10.1016/j.annonc.2022.07.081
93. Meric-Bernstam F, Rothe M, Mangat PK et al. Cobimetinib plus vemurafenib in patients with solid tumors with BRAF mutations: results from the Targeted Agent and Profiling Utilization Registry study. *JCO Precis Oncol* 2023;7:e2300385. DOI:10.1200/PO.23.00385.

15 Authors' Affiliations

Prof. Dr. med. Dirk Arnold

Asklepios Tumorzentrum Hamburg
Asklepios Klinik Altona
Onkologie und Palliativmedizin, mit Sektionen
Hämatologie und Rheumatologie
Paul-Ehrlich-Str. 1
22763 Hamburg
d.arnold@asklepios.com

Prof. Dr. med. Markus Borner

ONCOCARE am Engeriedspital
Riedweg 15
CH-3012 Bern
markus.borner@hin.ch

Prof. Dr. med. Karel Caca

Klinikum Ludwigsburg
Klinik für Innere Medizin, Gastroenterologie, Hämato-Onkologie
Posilipostr. 4
71640 Ludwigsburg
karel.caca@rkh-kliniken.de

Prof. Dr. med. Irene Esposito

Universitätsklinikum Düsseldorf
Institut für Pathologie
Moorenstr. 5
40225 Düsseldorf
irene.esposito@med.uni-duesseldorf.de

Prof. Dr. Dr. Thorsten Oliver Götze

Krankenhaus Nordwest
Institut für Klinisch-Onkologische Forschung
Steinbacher Hohl 2-26
60488 Frankfurt
goetze.thorsten@khnw.de

Dr. med. Klaus Kraywinkel

Zentrum für Krebsregisterdaten
Robert Koch-Institut
General-Pape-Straße 62-66
12101 Berlin
k.kraywinkel@rki.de

Prof. Dr. med. Jens Ricke

Klinikum der Universität München
Klinik und Poliklinik für Radiologie
Marchioninstr. 15
81377 München
jens.ricke@med.uni-muenchen.de

Prof. Dr. med. Daniel Seehofer

Universitätsklinikum Leipzig
Klinik und Poliklinik für Viszeral-, Transplantations-,
Thorax- und Gefäßchirurgie
Bereich Hepatobiliäre Chirurgie & Viszerale Transplantation
Liebigstraße 20
04103 Leipzig
daniel.seehofer@medizin.uni-leipzig.de

PD Dr. med. Marianne Sinn

Universitätsklinikum Hamburg-Eppendorf
II. Medizinische Klinik und Poliklinik
Onkologie, Hämatologie, KMT mit Sektion Pneumologie
Martinistr. 52
20246 Hamburg
ma.sinn@uke.de

PD Dr. med. Alexander Stein

Hämatologisch-Onkologische Praxis Eppendorf
Eppendorfer Landstr. 42
20249 Hamburg
stein@hope-hamburg.de

Prof. Dr. med. Arndt Vogel

General Hospital/Princess Margaret Cancer Center Toronto
Longo Family Chair in Liver Cancer Research
ON M5G 2C4 Toronto
vogela@me.com

Prof. Dr. med. Henning Wege

Klinikum Esslingen
Klinik für Allgemeine Innere Medizin,
Onkologie / Hämatologie, Gastroenterologie und Infektiologie
Hirschlandstr. 97
73730 Esslingen
h.wege@klinikum-esslingen.de

PD Dr. Thomas Winder

Klinik Hirslanden
Witellikerstr. 40
CH-8032 Zürich
thomas.winder@hin.ch

16 Disclosure of Potential Conflicts of Interest

according to the [rules of DGHO, OeGHO, SGH+SSH, SGMO](#)

Author	Employer ¹	Consulting / Expert opinion ²	Shares / Funds ³	Patent / Copyright / License ⁴	Fees ⁵	Funding of scientific research ⁶	Other financial relations ⁷	Personal relationship with authorized representatives ⁸
Arnold, Dirk	Asklepios Tumorzentrum Hamburg AK Altona	Yes Astra Zeneca, Advisory Board Amgen, AstraZeneca, Bayer, Boehringer Ingelheim, Boston Scientific, Bristol Meyer Squibb, Daiichi Sankyo, Merck Sharp and Dome, Merck Serono, Pierre Fabre Pharma, Roche, Sanofi, Seagen, Servier, Takeda	No	No	Yes ACE Oncology, CME Provider Amgen Aptitude Health, CME Provider art tempi media CME Provider Astra Zeneca Bayer Bristol Meyer Squibb Clinical Care Options (CCO), CME Provider Eli Lilly From Research to Practice, CME Provider Imedex, CME Provider Ipsen MedAhead (Austria), CME Provider Merck (Serono) KGaA Merck, Sharp and Dome Pharma-Cept Pierre Fabre Pharma PRMA Consulting, CME Provider Roche Samsung Bioepis Sanofi (Genzyme) Servier streamitup Germany, CME Provider Tactics MD LLC - CME Provider Terumo WebMD Health Corp	Yes OncoLytics Inc.	Yes Reisekosten und/oder Kongressgebühren/ Registrierung Daiichi Sankyo	No
Borner, Markus	ONCOCARE am Engeriedspital, Bern	No	No	No	No	No	No	No
Caca, Karel	Klinikum Ludwigsburg Klinik für Innere Medizin, Gastroenterologie, Hämatologie Onkologie Posillipstr. 4 71640 Ludwigsburg	No	No	No	Yes Amgen, BMS, Falk, , Ovesco	Yes AIO	No	No
Esposito, Irene	Universitätsklinikum Düsseldorf	Yes Bristol Myers Squibb	No	No	Yes Incyte Falk Foundation Bristol Myers Squibb	No	No	No
Götze, Thorsten Oliver	Krankenhaus Nordwest Frankfurt	Yes	No	No	Yes	Yes	No	No

Author	Employer ¹	Consulting / Expert opinion ²	Shares / Funds ³	Patent / Copyright / License ⁴	Fees ⁵	Funding of scientific research ⁶	Other financial relations ⁷	Personal relationship with authorized representatives ⁸
		advisory role:Lilly, MSD Sharp & Dohme, B , Servier, Roche, Ipsen; Amgen, AstraZeneca, Bayer, BMS, Daiichi Sankyo, FoundationMedicine, Lilly, MCI, Novartis, Roche, Sanofi Aventis, Servier, Deciphera, Boehringer-Ingelheim speaker for Lilly, MCI, MSD Sharp & Dohme;			Lilly, MSD Sharp & Dohme, Servier, Roche, Ipsen Amgen, AstraZeneca, Bayer, BMS, Daiichi Sankyo, FoundationMedicine, MCI, Novartis, Roche, Sanofi Aventis, Deciphera, Boehringer-Ingelheim	research grants from German Research Foundation (DFG), Gemeinsamer Bundesausschuss, Deutsche Krebshilfe, AstraZeneca, and Lilly., INCYTE; Taiho; Servier;		
Kraywinkel, Klaus	Robert Koch-Institut, Berlin	No	No	No	No	No	No	No
Ricke, Jens	Ludwig-Maximilians-Universität München	Yes Bayer Healthcare Terumo Boston Scientific Sirtex Roche BMS Eisai	No	No	Yes Sirtex Boston Scientific LIAM GmbH	Yes Sirtex Bayer Healthcare	No	No
Seehofer, Daniel	Universitätsklinikum Leipzig	Yes Astellas, Novartis, SIRTEX, BTG, Johnson&Johnson, Olympus	No	No	Yes Astellas, Astra Zeneca, Novartis, SIRTEX, BTG, Johnson&Johnson, Olympus, Abbvie, Bayer, Eisai, MSD/Merck,	No	No	No
Sinn, Marianne	Universitätsklinikum Hamburg-Eppendorf, 2. Medizinische Klinik, Zentrum für Onkologie Charite-Universitätsmedizin Berlin, CONKO-Studiengruppe Projektkoordinatorin Onkopedia GI-Tumoren	Yes Amgen, AstraZ, Sanofi, Servier, MSD	No	No	Yes BMS, Pierre Fabre	Yes Astra Z, BMS, Biontech, MSD, Roche, Servier (Institution)	No	No
Stein, Alexander	Hämatologisch-Onkologische Praxis Eppendorf	Yes Teilnahme an Advisory Boards Amgen, Beigene, BMS, Merck, MSD, Roche, Servier, Taiho, Takeda	No	No	Yes Amgen, Beigene, BMS, Merck, MSD, Roche, Servier, Taiho, Takeda	Yes	No	No

Author	Employer ¹	Consulting / Expert opinion ²	Shares / Funds ³	Patent / Copyright / License ⁴	Fees ⁵	Funding of scientific research ⁶	Other financial relations ⁷	Personal relationship with authorized representatives ⁸
						Forschungsunterstützung (institutionell): BMS, Deutsche Krebshilfe, Servier, Pierre Fabre, MSD		
Vogel, Arndt	Medizinische Hochschule Hannover	No	No	No	Yes Amgen, Roche, Bayer, Sanofi, BMS, Lilly, Novartis, Eisai, AstraZeneca, Merck, Incyte, Ipsen, PierreFabre, MSD, Sirtex, BTG, Servier, Terumo.	No	No	No
Wege, Henning	Klinikum Esslingen Universitätsklinikum Hamburg-Eppendorf	Yes AstraZeneca, Taiho, Incyte, MSD, Pfizer	No	No	Yes AstraZeneca, Taiho, Incyte, MSD, Pfizer	No	No	No
Winder, Thomas	Universitäres Lehrkrankenhaus Feldkirch, Österreich	Yes BMS, Merck, MSD, Roche, Novartis, Servier, Takeda, Amgen, Daichy Sankyo, Astra Zeneca,	No	No	Yes BMS, Merck, MSD, Roche, Novartis, Servier, Takeda, Amgen, Daichy Sankyo, Astra Zeneca,	No	No	No

Legend:

¹ - Current employer, relevant previous employers in the last 3 years (institution/location).

² - Activity as a consultant or expert or paid participation in a scientific advisory board of a company in the health care industry (e.g., pharmaceutical industry, medical device industry), a commercially oriented contract research organization, or an insurance company.

³ - Ownership of business shares, stocks, funds with participation of companies of the health care industry.

⁴ - Relates to drugs and medical devices.

⁵ - Honoraria for lecturing and training activities or paid authors or co-authorships on behalf of a company in the health care industry, a commercially oriented contracting institute or an insurance company.

⁶ - Financial support (third-party funds) for research projects or direct financing of employees of the institution by a company in the health care industry, a commercially oriented contract institute or an insurance company.

⁷ - Other financial relationships, e.g., gifts, travel reimbursements, or other payments in excess of 100 euros outside of research projects, if paid by an entity that has an investment in, license to, or other commercial interest in the subject matter of the investigation.

⁸ - Personal relationship with an authorized representative(s) of a healthcare company.