

# CUP Syndrome – Cancer of Unknown Primary

Recommendations from the society for diagnosis and therapy of haematological and oncological diseases

## **Publisher**

DGHO Deutsche Gesellschaft für Hämatologie und  
Medizinische Onkologie e.V.  
Bauhofstr. 12  
D-10117 Berlin

Executive chairman: Prof. Dr. med. Andreas Hochhaus

Phone: +49 (0)30 27 87 60 89 - 0

[info@dgho.de](mailto:info@dgho.de)

[www.dgho.de](http://www.dgho.de)

## **Contact person**

Prof. Dr. med. Bernhard Wörmann  
Medical superintendent

## **Source**

[www.onkopedia-guidelines.info](http://www.onkopedia-guidelines.info)

The information of the DGHO Onkopedia Web Site is not intended or implied to be a substitute for professional medical advice or medical care. The advice of a medical professional should always be sought prior to commencing any form of medical treatment. To this end, all component information contained within the web site is done so for solely educational purposes. DGHO Deutsche Gesellschaft für Hämatologie und Onkologie and all of its staff, agents and members disclaim any and all warranties and representations with regards to the information contained on the DGHO Web Site. This includes any implied warranties and conditions that may be derived from the aforementioned web site information.

# Table of contents

<b>1 Summary</b> .....	<b>3</b>
<b>2 Basics</b> .....	<b>3</b>
2.1 Definition and basic information .....	3
2.2 Epidemiology .....	3
2.3 Pathogenesis.....	4
2.4 Risk factors .....	4
<b>3 Prevention and early detection</b> .....	<b>4</b>
3.1 Prevention.....	4
<b>4 Clinical image</b> .....	<b>4</b>
4.1 Symptoms.....	4
<b>5 Diagnosis</b> .....	<b>4</b>
5.1 Diagnostic criteria (histology, primary tumor and classification).....	4
5.1.1 Histology, immunohistochemistry, molecular genetics, immunogenicity .....	4
5.1.2 Primary tumors .....	7
5.1.3 Distribution .....	7
5.2 Diagnostic procedures .....	7
5.2.1 Initial diagnosis.....	8
5.2.1.1 Basic program.....	8
5.2.1.2 Further diagnostics: Level I.....	9
5.2.1.3 Further diagnostics: Level II.....	9
5.4 Prognostic factors, survival.....	13
<b>6 Therapy</b> .....	<b>14</b>
6.1 Treatment structure .....	14
6.1.1 Localized stages .....	15
6.1.1.1 Cervical lymph node metastases .....	15
6.1.1.1.1 Level I, II, III, V, VI (not Level IV = supraclavicular).....	15
6.1.1.1.2 Level IV (supraclavicular = deep inferior deep cervical lymph nodes) ..	16
6.1.1.2 Axillary lymph node metastases (preferably in women).....	16
6.1.1.3 Regionally limited thoracic/mediastinal lymph nodes.....	17
6.1.1.4 Solitary inguinal lymph nodes.....	18
6.1.1.5 Solitary brain metastasis .....	18
6.1.1.6 Solitary lung metastasis .....	18
6.1.1.7 Solitary bone metastasis .....	19
6.1.1.8 Solitary hepatic metastasis / oligometastasis in the liver.....	19
6.1.1.9 Solitary metastasis of malignant melanoma.....	19

6.1.1.10 Solitary skin or soft tissue metastasis other than melanoma, incl. Merkel cell carcinoma ..	20
6.1.2 Advanced stages ..	20
6.1.2.1 Extragonadal germ cell tumors.....	20
6.1.2.2 Neuroendocrine tumors ..	20
6.1.2.2.1 Well-differentiated neuroendocrine tumors - NET Grades 1 and 2.....	20
6.1.2.2.2 Undifferentiated neuroendocrine (small cell) carcinoma ..	21
6.1.2.3 Women with peritoneal carcinomatosis due to adenocarcinoma.....	21
6.1.2.4 Hormone-sensitive carcinoma ..	22
6.1.2.4.1 ER (estrogen receptor)-positive carcinoma.....	22
6.1.2.4.2 AR (androgen receptor)-positive carcinoma ..	22
6.1.2.5 Colon-type adenocarcinoma (immunohistochemically CK7-, CK20+, CDX2+)	22
6.1.2.6 Renal-type carcinoma (clear-cell or papillary, immunohistochemical PAX8+, PAX2+, CD10+, Racemase+)	22
6.1.3 Prognostically unfavorable manifestations ..	23
6.1.3.1 Adenocarcinoma (ACUP) / undifferentiated carcinoma (UCUP) / squamous cell carcinoma (SqCUP) / malignant tumor NOS (not otherwise specified)	23
6.1.3.2 Chemotherapy for adenocarcinoma (ACUP) / undifferentiated carcinoma (UCUP)	24
6.1.3.3 Chemo-/radiotherapy for squamous cell carcinoma (SqCUP) ..	25
6.3 Special situations.....	25
6.3.1 Skeletal metastasis.....	25
<b>8 Monitoring and follow-up ..</b>	<b>26</b>
8.2 Follow-up ..	26
<b>9 References.....</b>	<b>26</b>
<b>16 Authors' Affiliations.....</b>	<b>31</b>
<b>17 Disclosure of Potential Conflicts of Interest ..</b>	<b>32</b>

# CUP Syndrome - Cancer of Unknown Primary

**ICD-10:** C80.-

**Date of document:** June 2023

## Compliance rules:

- [Guideline](#)
- [Conflict of interests](#)

**Authors:** Gerdt Hübner, Tilmann Bochtler, Markus Borner, Herbert Stöger, Kai Neben, Thomas Ernst, Klaus Kraywinkel, Lena Weiss

## 1 Summary

The term CUP syndrome (= Cancer of Unknown Primary) covers a very heterogeneous clinical picture. CUP syndrome is defined as a histologically or cytologically confirmed malignancy with unknown primary tumor after completion of standardized primary diagnostics.

Therapy is based on defined subtypes, characterized by localization, histology, immunohistochemistry, molecular tumor profile, and also by gender and risk factors (primarily smoking). In the case of prognostically favorable subtypes, a curative therapy approach is possible.

This guideline has been updated in close coordination with the current guideline of the European Society for Medical Oncology (ESMO) [20].

## 2 Basics

### 2.1 Definition and basic information

The term CUP syndrome (= Cancer of Unknown Primary, cancer with unknown primary tumor) refers to a multifaceted oncological clinical picture. It is defined as

- Histologically or cytologically confirmed malignant tumor
- Tumor of origin unknown/uncertain after completion of standardized primary diagnostic procedures

### 2.2 Epidemiology

The incidence of CUP has been decreasing since the turn of the century in Western industrialized countries and is 4-15/100,000 inhabitants/year, corresponding to 1-3% of all cancer cases [1]. The proportion of patients with histo-/cytologically defined disease in the registry databases is only 20-60%; however, the diagnostic procedures may have been incomplete. Evaluations of the Center for Cancer Registry Data of the Robert-Koch-Institute (RKI) showed an incidence of about 11,000 cases per year in 2013-2014, although the authors point out the difficulty to distinguish between CUP and inaccurately documented cases in cancer registry data and assume a lower number of true CUP [74]. If only cases are taken into account that do not contain any indication of a primary tumor, even via the TNM stage and the variable "diagnosis confirmation", the data of the RKI in 2017-2019 showed approximately 4,000 new CUP cases reported annually from clinics or pathologies, in addition to about 850 cases annually that became known to the registry only via the death certificate (Death Certificate Only = DCO) and for which the cause of death was coded as C80.0 (ICD-10: malignant neoplasm, primary localization unknown). Thus, at the most recent count, just under 5,000 CUP cases per year could be

estimated in Germany, which corresponds to 1% of all new cancer cases. According to RKI data, about three quarters of patients affected die within one year after diagnosis, and around 10% are alive after 5 years. In the case of CUP with squamous cell histology, the prognosis is significantly better, with more than 30% still alive after 5 years. Overall, mortality in CUP (unchanged in 2020 as compared to previous years) takes the 6th place (4.6%) of all cancer deaths in Germany [2]. The peak age of onset is 53 to 62 years, and men are affected slightly more often than women (around 1.1:0.9) [3].

## **2.3 Pathogenesis**

Etiology and pathogenesis are largely hypothetical. Typically, there is a growth advantage of metastases over the primary tumor. A primary tumor may have spontaneously regressed or been removed unnoticed, e.g., as a "naevus" or as an "adenoma." A regressing proportion (due to more intensive and better diagnostics) results from a lack of differentiation between the original tumor and metastases, e.g., in liver or lung. Stem cell research as well as tumor genomics allow an approach to explain the phenomenon of CUP: tumor stem cells can give rise to daughter cells that do not grow locally but are capable of forming distant metastases if the microenvironment is favorable. This occurs more frequently with certain (developmental and mutational) signatures [4, 5, 6]. It is also discussed whether a malignancy may manifest itself primarily with metastases even in the absence of an original tumor ("primary metastatic cancer") [76].

## **2.4 Risk factors**

Smoking significantly increases the incidence (hazard ratio around 3.7) [20], as well as diabetes and obesity (HR around 2.0) [7, 8].

# **3 Prevention and early detection**

## **3.1 Prevention**

Specific recommendations are not established, due to the nature of cancer with unknown primary tumor.

# **4 Clinical image**

## **4.1 Symptoms**

CUP syndrome includes a multifaceted clinical picture. Multiple manifestations are possible and must be differentiated. Clearly separated subgroups can be distinguished, with specific therapies required.

# **5 Diagnosis**

## **5.1 Diagnostic criteria (histology, primary tumor and classification)**

### **5.1.1 Histology, immunohistochemistry, molecular genetics, immunogenicity**

The distribution of histological types in CUP syndrome is summarized in [Table 1](#).

**Table 1: Histological types of CUP syndrome [3]**

Histology	%
Adenocarcinoma	40-60
Undifferentiated carcinoma	15-30
Squamous cell carcinoma	15-20
Small cell/neuroendocrine carcinoma	3-5
other	1-3

Characterization using immunohistochemical markers and molecular biological methods is of paramount importance. Clinical findings and specific questions must be discussed with the pathologist in order to obtain the best possible information in a short time. However, due to the overlapping and aberrant expression of structural proteins in the tumor tissue, an exact assignment of the primary tumor may still be impossible; in almost all cases, however, a treatment-relevant containment of the spectrum of possible primary tumors can be obtained.

First, a lineage classification is required: carcinoma vs. others (hematologic malignancies, sarcomas, melanomas, etc.); in the case of carcinomas the tissue origin (adeno-, squamous-, undifferentiated, neuroendocrine), then further subclassifications [9, 10, 11, 28]. Table 2 provides an overview of the most important immunohistochemical markers; marker panels that go beyond these are listed - according to clinical and histological suspected diagnosis - in the ESMO guidelines [20]. Markers for the detection of immune checkpoint blockade-sensitive tumors are part of the diagnosis (PD1/PDL1, MMR (mismatch repair), microsatellite status, TMB [tumor mutational burden], and others) [12, 13, 14]. Molecular signatures are already providing new insights into tumor biology and are expected to allow for a more specific classification in the near future. Comprehensive molecular next-generation sequencing (NGS) is recommended in the ESMO guidelines and should be used when available and if individual treatment options may be realized [20].

**Table 2: Selection of important immunohistochemical markers**

Marker	Tumor type	Expression pattern	Organ Assignment
Pan-cytokeratin (Pan-CK)	Carcinoma	CK 7+, CK 20-	Lung, breast, gall bladder, pancreas, ovary, and many others
Vimentin	Sarcoma, melanoma; rarely also carcinoma (e.g., kidney, ovary, uterus)	CK 7-, CK 20+	Colon; Merkel cell, rarely stomach
Melan A, HMB 45	Melanoma	CK 7+, CK 20+	Pancreas, stomach, ovary, gall bladder, urothelium, and others
LCA (CD45)	Leukemia, lymphoma	CK 7-, CK 20-	Liver, neuroendocrine, kidney, prostate, lung
PLAP, OCT4, SALL4	Germ cell tumor	CDX2	Colon/GI tract; rarely also ovary, bladder, lung
HepPar-1, Arginase-1	Liver	GCDFP15; Mammoglobin	Breast, salivary glands
TTF-1	Lung, thyroid gland	GATA3	Breast, urothelium; uterus, pancreas, eccrine gland, and others
Napsin A	Lung, papillary carcinoma of the kidney and thyroid gland	ER	Breast, uterus; rarely kidney, ovary, lung, liver, and others
Chromogranin A; Synaptophysin	Neuroendocrine neoplasia	Thyroglobulin	Thyroid
CK 5/6; p40; p63	Squamous cell carcinoma, urothelial carcinoma	WT1	Ovary, mesothelium, and others
AR	Prostate; triple-neg. breast cancer, and others	PAX8	Ovary, uterus, kidney, urothelium, thyroid
PSA, NXX3.1, PSMA	Prostate		

*Legend:*

*AR - androgen receptor, CK - cytokeratin, ER - estrogen receptor, GATA - GATA binding protein, GCDFP - gross cystic disease fluid protein, HMB - human melanoma black, LCA - leukocyte common antigen, PSA - prostate specific antigen, TTF - tissue transcription factor, WT - Wilms tumor antibody*

Molecular characterization using tests to detect gene expression, DNA methylation or micro RNA patterns allow assignment of the possible primary tumor with 85-90% accuracy [15, 16, 17]. Improved survival due to such classification has not yet been shown in randomized trials [18, 71, 72], so these tests are not currently recommended as standard of care.

The use of NGS or other large-scale sequencing platforms to generate a molecular signature and to screen tumor tissue for actionable targets, i.e. for therapeutically relevant driver mutations, is internationally recommended in patients in whom a therapeutic consequence is expected, and is a standard diagnostic procedure in CUP syndrome in all patients in good performance status [19, 20]. Genetic alterations are found in more than 85% of cases, and in molecular tumor boards well-founded treatment recommendations can be made for approximately one-third of patients on the basis of this diagnosis. The results of a large international phase II trial with over 600 randomized patients (CUPISCO) to test this strategy are expected at the end of 2023 [21].

As markers of potential sensitivity to immune checkpoint blockade, microsatellite instability and TMB-high (>10 mutations/Megabase) are well established in CUP, as is relevant PDL1 expression - but a cutoff for treatment recommendations is currently not clearly defined [12, 22, 23].



### 5.1.2 Primary tumors

Identification of the primary tumor during the course of the disease or at autopsy remains exceptional (<10%). Historical autopsy series are no longer helpful in suggesting possible tumors of origin. Exclusion or detection of late recurrence of antecedent tumor disease, which is a relatively common event in breast and renal carcinomas, may be relevant for treatment decisions. Comparative molecular NGS of prior malignancy and putative CUP syndrome can help prevent recurrences of prior malignancy from being misinterpreted as CUP [78].

CUP syndromes with cervical lymph node metastases in the upper and middle third of the neck represent a special subentity. In this case, the primary tumor is diagnosed more frequently in HPV-positive tumors [24], see Table 3.

**Table 3: Primary tumors in cervical lymph node metastases**

Localization of the primary tumor	%
HPV-pos: Oropharynx (predominantly)	80 - >90
HPV-neg: Head and neck tumors (including oropharynx)	60 - 80
Lungs	15 - 25
Thyroid gland	5 - 10
all others together	<5%

### 5.1.3 Distribution

The distribution pattern of metastasis from patients with CUP syndrome is found in Table 4.

**Table 4: Initial manifestation in CUP syndrome [3]**

Manifestation	%
Primary localized (solitary/oligometastasis or involvement of only one lymph node region)	15-25
Primary disseminated	75-85
Lymph nodes	40-45
Liver	30-40
Skeleton	25-35
Lungs	30-40
Pleura	5-15
Peritoneum	5-10
CNS	5-10
Adrenal glands	~ 6%
Skin	~ 4%

## 5.2 Diagnostic procedures

Diagnostics are prognosis- and therapy-oriented. This includes staging and detection of prognostically more favorable defined entities, (see Table 7 and Figure 1), establishing a working diagnosis or identifying the primary tumor.

Histological (and not only cytological) diagnostics should be performed. Histology, immunohistochemistry and molecular biology provide indications of therapeutic relevance by narrowing the spectrum of possible primary tumors, for the formulation of a working diagnosis as well as for therapy planning. Material collection for histology is therefore required **early** in the primary diagnostic work-up.

## 5.2.1 Initial diagnosis

### 5.2.1.1 Basic program

At the beginning of the diagnostic process there is a basic diagnostic program, see [Table 5](#).

**Table 5: Basic diagnostic program in CUP syndrome [10, 19, 20]**

Diagnosics	Notes
Medical history	
Physical examination	In men, including testicular palpation In women, including examination of the mammae
Tissue sample	Histology! Sufficient material for immunohistochemistry and molecular genetics
CT thorax CT abdomen with pelvis	Better: early PET-CT
PET-CT	For head and neck CUP In case of singular metastasis or oligometastasis with the prospect of local ablative treatment (tumor board decision)
Gastrointestinal endoscopy	If gastrointestinal primary is suspected
Gynecological examination Mammography and breast sonography Vaginal sonography if necessary	For women
Laboratory incl. biomarkers	Routine chemistry incl. differential blood count, LDH, albumin, AP Tumor marker: AFP In men additionally: PSA, $\beta$ -hCG

With this basic diagnosis, a search for common primary tumors, an orienting staging and - if not clinically obvious - the determination of the optimal localization for tissue sampling can be achieved in a short time. Examination of asymptomatic regions beyond the basic program is not useful. Diagnostics repeated during the course do not contribute to primary tumor identification. Only rarely is the primary tumor symptomatic during the course of the disease and thereby identified (<10%).

PET-CT **at the beginning of** the diagnosis is desirable, but - except for cervical lymph node metastases with unknown primary tumor - not accepted by the health care authorities (GBA) in Germany and also not part of international guidelines [10, 19, 20]. PET-CT allows rapid staging, additional cross-sectional CT and/or MRI examinations can often be omitted, and further diagnostics can be more focused. A recent meta-analysis concluded that therapy-relevant findings are found by PET-CT in one third of patients [25]. Identification of the primary tumor is successful in 18-28%, previously unknown metastases are found in 10-19%.

The ESMO guideline recommends the use of PET-CT additionally in singular metastases or oligometastatic disease, if there is a prospect of local ablative therapy in curative intention with surgery and / or radio(chemo)therapy [20]. This is to exclude possible further metastases before local treatment. Before PET-CT is performed in Germany, an explanatory tumor board decision and, if necessary, an application for cost coverage to the health insurance company is recommended, which should be made with reference to the ESMO guideline and the Onkopedia

guideline available here. In most cases the time spent for awaiting the results of this approach is not worthwhile the possible additional information.

### 5.2.1.2 Further diagnostics: Level I

Supplementary examinations are performed specifically according to the patient's history, findings, and working diagnosis. Above all, a search should be made for therapeutically relevant, prognostically favorable groups, see Table 7. Further diagnostics in the first stage are based on the medical history, the localization of the tumor manifestations, and histology. Recommendations are summarized in Table 6.

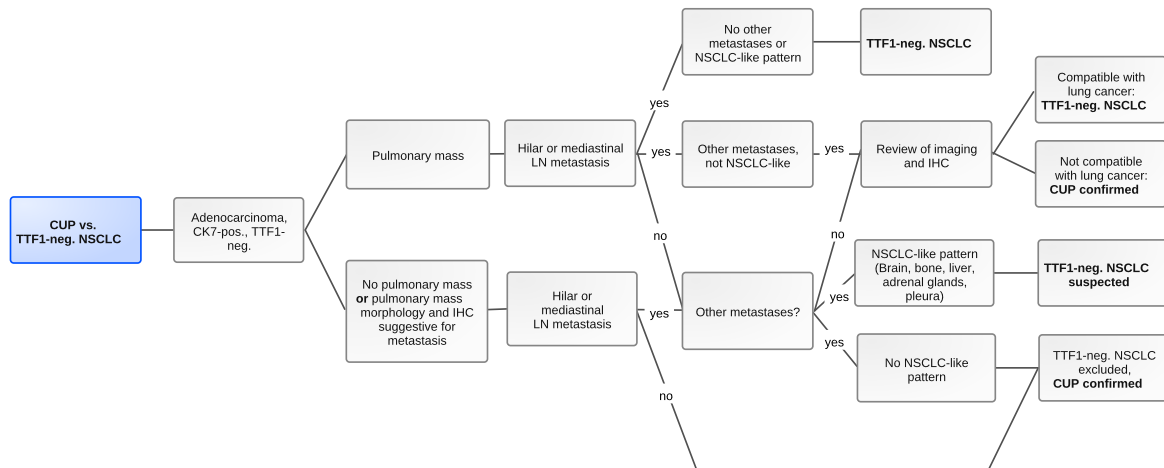
**Table 6: Further diagnostics for CUP syndrome**

Manifestation	Notes
Localized (solitary metastasis or involvement of a lymph node region)	<ul style="list-style-type: none"> <li>Intensive diagnostics locoregionally</li> <li>PET-CT [10, 20]</li> <li>Cerebral MRI</li> </ul>
Involvement of cervical lymph nodes	<ul style="list-style-type: none"> <li>PET-CT <i>before</i> panendoscopy [20, 26]</li> <li>Panendoscopy, for HPV-pos. tumors with tongue base biopsies and ipsi- or bilateral tonsillectomy [26]</li> <li>Endoscopic narrow-band imaging if possible</li> </ul>
Involvement of axillary lymph nodes in women	<ul style="list-style-type: none"> <li>Skeletal scintigraphy</li> <li>MRI of the mammae [19, 20]</li> </ul>
Neuroendocrine tumors (grade I-II)	<ul style="list-style-type: none"> <li>68-gallium somatostatin receptor PET-CT [57]</li> <li>Exploratory laparoscopy/laparotomy if R0 resection of the metastasis(es) appears achievable [27]</li> </ul>
Neuroendocrine tumors (grade III-IV)	<ul style="list-style-type: none"> <li>Bronchoscopy; if required, endobronchial ultrasound</li> </ul>
Histology and immunohistochemistry matching 'upper GI' or 'pancreaticobiliary' adenocarcinoma	<ul style="list-style-type: none"> <li>Gastroscopy, endoscopic ultrasound (including distal esophagus and gastric wall), MRI pancreas/upper abdomen with MRCP.</li> </ul>
Colon-typical adenocarcinoma (immunohistochemically CK7-, CK20+, CDX2+)	<ul style="list-style-type: none"> <li>Colonoscopy, or eventually, capsule endoscopy / push enteroscopy</li> </ul>
all others	<ul style="list-style-type: none"> <li>Targeted examinations based on history, findings, histology, and staging</li> </ul>

### 5.2.1.3 Further diagnostics: Level II

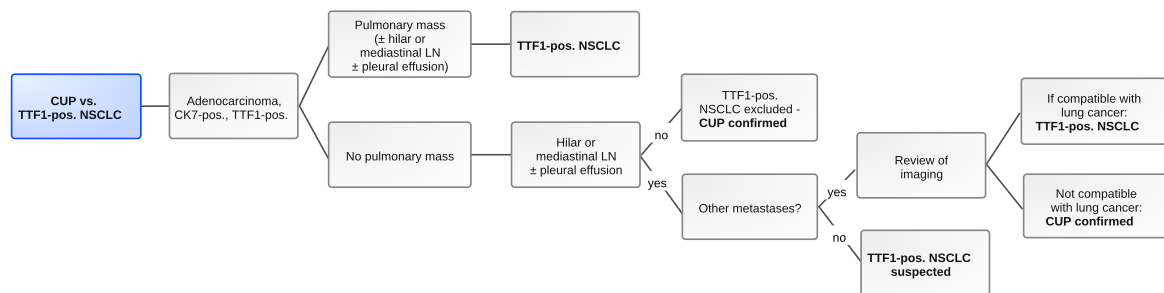
The first diagnostic program is followed by a second level according to tumor presentation and histology including immunohistochemistry. The following flow charts (Figure 1 - 7) are partial results of the CUPISCO study - the first international large prospective study with central pathology review and central expert review of each individual patient before inclusion in the study [28]. These algorithms use the criteria of immunohistochemistry, local lymph node stations, and distant metastases to provide guidance as to whether a malignant mass should be interpreted as a primary tumor or as a metastasis, thus facilitating the differential diagnosis between CUP syndrome and known tumor entities. The result is a much clearer definition of 'true' CUP patients. The algorithms have already been included in the current ESMO guidelines [20]. They are of essential practical importance.

**Figure 1: CUP vs TTF1-negative NSCLC**



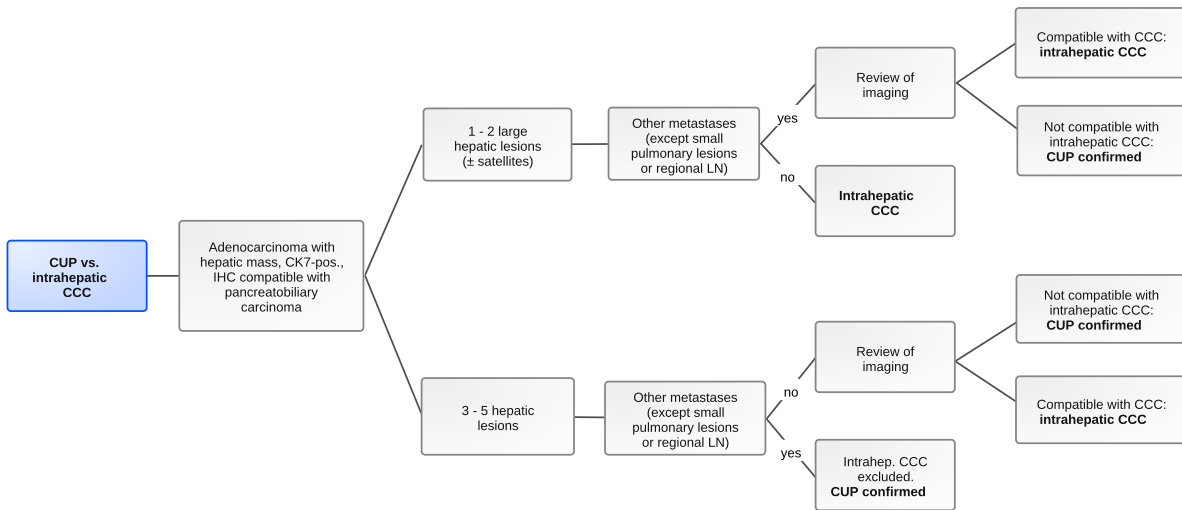
*Legend:*  
 CK - cytokeratin, IHC - immunohistochemistry, LN - lymph node, NSCLC - non-small cell lung cancer, TTF - thyroid transcription factor  
 NSCLC pattern: metastases to brain, skeleton, liver, adrenal gland, pleura

**Figure 2: CUP vs TTF1-positive NSCLC**



*Legend:*  
 CK - cytokeratin, LN - lymph node, NSCLC - non-small cell lung carcinoma, TTF - thyroid transcription factor

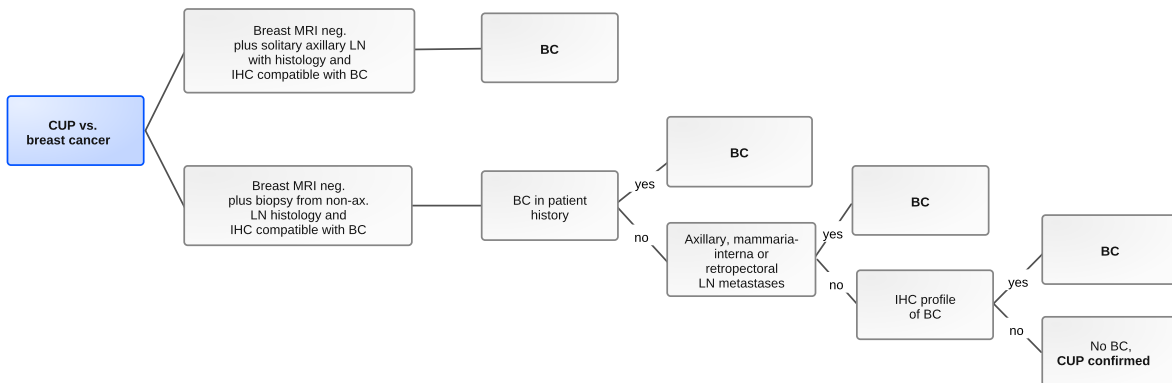
**Figure 3: CUP vs. intrahepatic cholangiocellular carcinoma**



Legend:

CCC - cholangiocellular carcinoma, CK - cytokeratin, IHC - immunohistochemistry, LN - lymph node

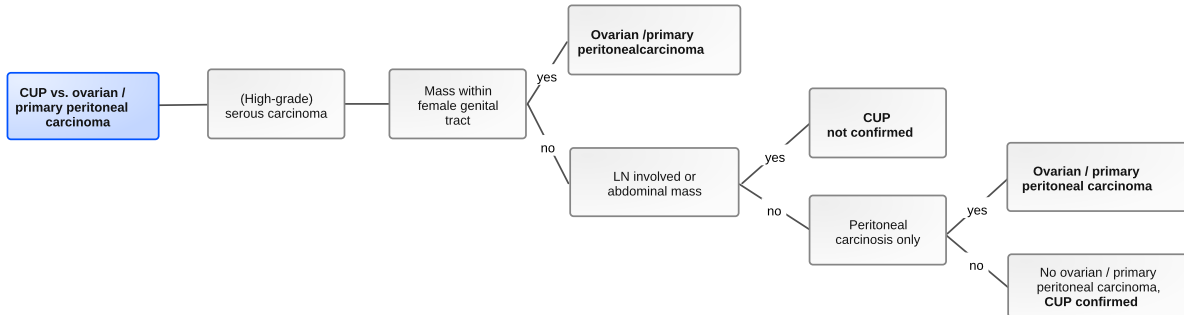
**Figure 4: CUP vs. breast cancer**



Legend:

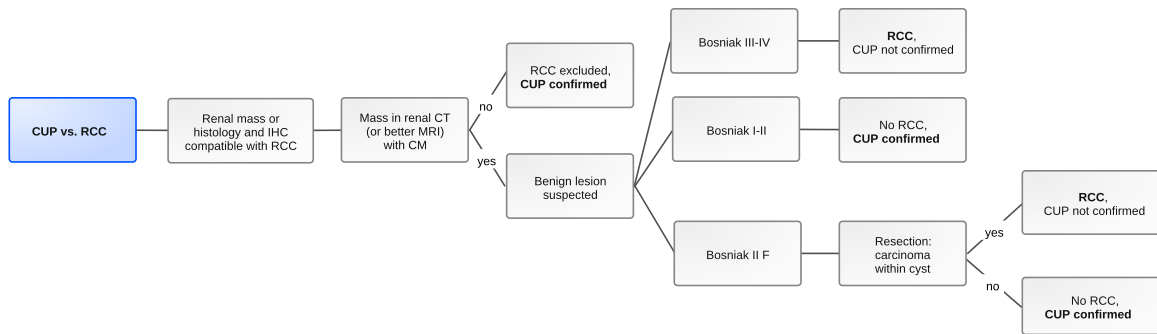
BC - breast cancer, IHC - immunohistochemistry, LN - lymph node, MRI - magnetic resonance imaging

**Figure 5: CUP vs. ovarian / primary peritoneal carcinoma**



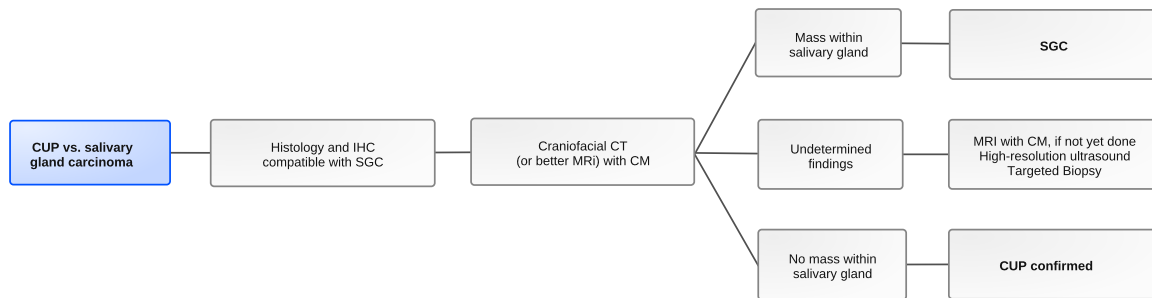
Legend:  
LN - lymph node

**Figure 6: CUP vs. RCC (renal cell carcinoma)**



Legend:  
CT - computed tomography, IHC - immunohistochemistry, CM - contrast media, MRI - magnetic resonance imaging, RCC - renal cell carcinoma; Bosniak - classification of renal cysts

**Figure 7: CUP vs. salivary gland carcinoma**



*Legend:*

*SGC - salivary gland carcinoma, CT - computed tomography, IHC - immunohistochemistry, CM - contrast medium, MRI - magnetic resonance imaging*

## 5.4 Prognostic factors, survival

Median survival in CUP syndrome in published studies is 6-10 months, with 1-year survival rates of 25-40% and 5-year survival rates of 5-15% [3]. Registry data indicate a median survival of approximately 3 months with a 1-year survival rate of 20% [20].

Prognostic factors are general condition, serum albumin level, LDH, comorbidity, number of metastases, and presence of liver metastases. However, the factors are not predictive, and thus an individual estimation of survival is not feasible [29].

However, it is important to distinguish between the so-called favorable subgroups and the larger group of those affected with an unfavorable prognosis ('unfavorable subset'). The subgroups with favorable prognosis are summarized in [Table 7](#).

**Table 7: Prognostically favorable subgroups in CUP syndrome**

Manifestation	Notes
Local (resectable) disease (single-site or oligometastatic CUP)	Solitary metastasis, surgically resectable oligometastasis or oligometastasis that can be irradiated with curative intent, involvement of only one lymph node region
Cervical lymph node metastasis of squamous or undifferentiated carcinoma (head and neck-like CUP)	CUP is not mentioned separately in the <a href="#">Onkopedia guideline Head and Neck Cancer</a> , but accounts for approximately 5%
Axillary lymph node metastases in women (breast-like CUP)	See <a href="#">Figure 4</a> see guideline <a href="#">Onkopedia Female Breast Cancer</a> (German Version only)
Colon-type adenocarcinoma (colon-like CUP)	Immunohistochemical CK7-, CK20+, CDX2+.
Renal cell carcinoma-type histology and immunohistochemistry (renal-like CUP)	Histology (clear cell / papillary) <b>and</b> immunohistochemistry (pos. for PAX8, PAX2, racemase and CD10), see <a href="#">guideline Renal cell carcinoma</a>
Specific histology	Does no longer count as CUP (e.g., melanoma, sarcoma, Merkel cell carcinoma, hematological neoplasia, etc.)
Peritoneal carcinomatosis due to high-grade serous adenocarcinoma in women (ovary-like CUP)	Does no longer count as CUP syndrome but: primary peritoneal carcinoma.
Extragenital germ cell tumor	Does no longer count as CUP syndrome. Can be reliably differentiated by IHC. Discuss with pathologists! Affects males < 50 years, poorly differentiated carcinoma, retroperitoneal/mediastinal/pulmonary, rapid progression, see <a href="#">Onkopedia Male Germ Cell Tumors</a> (German Version only)
Neuroendocrine tumors	Does no longer count as CUP syndrome. NET grade 1, 2 and 3: NET-specific therapy according to the NET guideline; NEC: see guideline <a href="#">Onkopedia Small-Cell Lung Cancer</a>

## 6 Therapy

### 6.1 Treatment structure

The treatment strategy is based on:

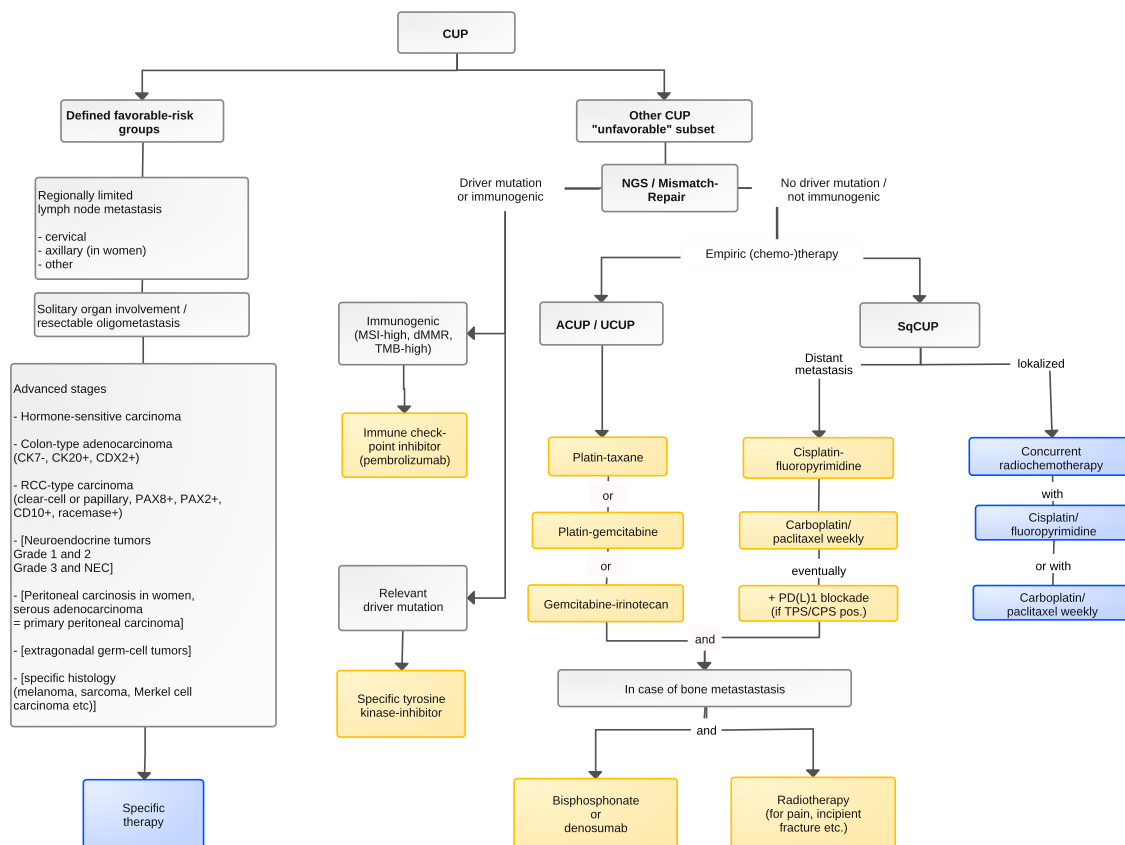
- the general condition and patient preferences
- the presence of a defined group, see [Table 7](#)
- the manifestation pattern
- histology/immunohistochemistry
- the immunogenicity of the tumor
- molecular tumor diagnostics including testing for driver mutations
- the working diagnosis.

Patients with CUP syndrome of a good-risk defined group receive an appropriate therapy, see chapter [6. 1. 1.](#) and chapter [6. 1. 2.](#) However, the majority of patients (approx. 70-85%) do not fall into this group and are summarized as 'unfavorable manifestations', see chapter [6. 1. 3.](#)

The treatment structure is summarized in [Figure 8.](#)



**Figure 8: Treatment structure in CUP syndrome**



**Legend:**

ACUP - adenocarcinoma, UCUP - undifferentiated carcinoma, SqCUP - squamous cell carcinoma, NEC - neuroendocrine carcinoma

■ curative intended therapy; ■ non-curative intended therapy;

**6.1.1 Localized stages**

In case of solitary metastasis, resectable oligometastasis (e.g., in the liver) or involvement of only one lymph node region, local radical therapy is performed with curative intent [3, 20]. If surgery is not possible for a singular metastasis or oligometastasis, radio(chemo)therapy should be considered as an alternative.

**6.1.1.1 Cervical lymph node metastases**

**6.1.1.1.1 Level I, II, III, V, VI (not Level IV = supraclavicular)**

Frequency and primary tumor

- Approximately 5% of all head and neck cancers, 70-90% men.
- 50% squamous cell carcinoma, 35% undifferentiated carcinoma; immunohistochemically almost always identifiable as squamous cell carcinoma (CK 5/6+, p63+), rarely adenocarcinoma and others.
- Locoregional primary tumors in 70-80% (head and neck, occasionally thyroid), approximately 15-25% lung carcinomas.
- Tumors with HPV DNA detection or p16 expression originate predominantly from the oropharynx (especially tonsils and base of tongue); prognosis is better than in HPV-negative tumors, radiotherapy may be limited to a smaller field (oropharynx). The oropharynx

must be explored very carefully; unilateral or bilateral tonsillectomy and, if necessary, mucosectomy of the base of the tongue is useful [30].

- 5-year survival according to N status: N1, 61%, N2, 51%, N3, 26%; extracapsular spread (ECE+), 57%, ECE-, 82% [26, 31, 32, 33].

#### Therapy [26, 30, 32, 34]

- For N1 stages without additional risk factors: (unilateral) functional neck dissection (FND) with or without postoperative radiation *or* primary definitive radiotherapy.
- For N2 stages without additional risk factors: (uni- or bilateral) functional neck dissection (FND) followed by postoperative radiotherapy *or* primary definitive radiotherapy *or* FND followed by concurrent radiochemotherapy.
- For N3 stages or additional risk factors (involvement of 2 or more lymph nodes, extranodal spread, R1 resection): uni- or bilateral FND if indicated; combined postoperative radiochemotherapy. Alternatively, neoadjuvant radiochemotherapy before FND may be reasonable.
- For adenocarcinoma: FND with postoperative radiotherapy. Cure is rare, but 2-year survival rate approx. 50%.

An overview of the procedure for CUP in the head and neck region after neck dissection is given in Table 8.

**Table 8: Procedure after neck dissection for head and neck CUP [35, 36, 37, 38]**

TNM	Treatment
pN1	Follow-up or unilateral RT
pN2a	Unilateral RT (+/- platinum-based chemotherapy for ECE+).
pN2b	Unilateral or bilateral RT (+/- platinum-based chemotherapy for ECE+).
pN2c, pN3, R1	Bilateral RT + platinum-based chemotherapy.

*Legend:*

RT - radiotherapy, ECE - extracapsular extension

#### 6.1.1.1.2 Level IV (supraclavicular = deep inferior deep cervical lymph nodes) [39]

##### Frequency and primary tumor

- Localized form is very rare, mostly disseminated disease.
- Adenocarcinoma 35%, lung cancer as primary tumor 50%, breast cancer 30%.
- "Virchow's gland": gastric cancer, but also germ cell tumor and others possible.

##### Therapy

- Squamous, undifferentiated, and adenocarcinoma: lymph node resection followed by radiotherapy.
- Neuroendocrine (small cell) carcinoma: see below: treatment like small cell lung cancer.

#### 6.1.1.2 Axillary lymph node metastases (preferably in women)

- In women, this represents a defined special case of the CUP syndrome.
- For differentiation of 'true' CUP vs. breast cancer, see Figure 4.

- As a rule, in women diagnosis and therapy as for nodal-positive breast cancer.

#### Frequency and primary tumor

- In women almost always (>75%), in men occasionally breast cancer as primary tumor (in men often BRCA-associated).
- Otherwise frequently lung cancer, occasionally amelanotic melanoma, malignant lymphoma, soft tissue sarcoma (immunohistochemistry!).
- 5-year survival 50-88%.

#### Therapy for adeno- or undifferentiated carcinoma [20, 40, 41]

- Axillary lymphadenectomy (level I + II)
  - Mastectomy or lumpectomy is not required.
- (Neo)adjuvant chemotherapy as in nodal-positive breast cancer, see [Onkopedia Female Breast Cancer](#)
  - followed by radiotherapy (including the ipsilateral mamma) as after breast-conserving surgery
  - followed by anti-hormonal therapy for receptor-positive tumor
  - additional anti-HER2 therapy for HER2-positive tumor.

#### Therapy for squamous cell carcinoma

- Axillary lymphadenectomy
- followed by irradiation including the infra- and supraclavicular lymph node regions.

### **6.1.1.3 Regionally limited thoracic/mediastinal lymph nodes**

#### Frequency and primary tumor

- This manifestation is rare; frequently, the primary tumor is identifiable (see [Figures 1, 2, and 4](#)).
- Primary tumors are often pulmonary, but thymic carcinoma, breast cancer, or primary mediastinal germ cell tumor should also be considered.
- In some cases, long-term survival after surgery or combined radiochemotherapy has been described.
- By means of immunohistochemistry, a closer assignment of the possible primary tumor is often possible.
- Always search for driver mutations and immunogenicity.

#### Complementary diagnostics

- PET-CT and bronchoscopy, if required EBUS (endobronchial ultrasound) or trans-esophageal ultrasound, see [Onkopedia Non-Small-Cell Lung Cancer](#).

#### Therapy

- Primary radiochemotherapy as for NSCLC, surgical resection including suspicious lung portions, if indicated; followed by radiotherapy/radiochemotherapy.
- If a significant driver mutation or immunogenicity is detected: see chapter [6.1.2.6](#).

#### **6.1.1.4 Solitary inguinal lymph nodes**

##### Frequency and primary tumor

- This manifestation is rare, then often due to a locoregional primary tumor (vulva, vagina, cervix, penis, urethra, urinary bladder, anus, lower extremity skin).

##### Complementary diagnostics

- Dermatologic examination, gynecologic examination, urologic examination, proctoscopy, cystoscopy; histology/immunohistochemistry (exclusion of amelanotic melanoma or soft tissue sarcoma), HPV status in tumor tissue.

##### Therapy

- Surgical resection
- followed by radiotherapy including the iliac lymphatic drainage pathways; if indicated, as radiochemotherapy with fluoropyrimidine-based chemotherapy.

#### **6.1.1.5 Solitary brain metastasis**

##### Frequency and primary tumor

- Identification of the primary tumor is successful in 50-75% of cases. In most cases it is a lung carcinoma, less frequently a breast carcinoma.

##### Complementary diagnostics

- Craniofacial MRI, PET-CT; biopsy for histology and immunohistochemistry (molecular pathology) mandatory.

##### Therapy [42, 43, 44]

- Surgical resection, if neurosurgically possible, postoperative radiotherapy of resection bed.
- Gamma knife or stereotactic radiotherapy for unresectable lesions <5cm.
- Whole-brain irradiation only in cases of incomplete resection or numerous foci or according to histologic findings (small-cell neuroendocrine carcinoma).

#### **6.1.1.6 Solitary lung metastasis**

##### Frequency and primary tumor

- It is crucial to distinguish this from primary lung cancer, see [Figures 1](#) and [Figure 2](#).
- Solitary lung metastases as the only tumor manifestation are extremely rare, usually multiple lesions are detected.

##### Therapy

- Atypical resection, frozen section, lobectomy if indicated, systematic lymphadenectomy if required.
- If indicated, radiotherapy or adjuvant chemotherapy, depending on histology and individual case.

### **6.1.1.7 Solitary bone metastasis**

#### Frequency and primary tumor

- Rare, usually multiple lesions.
- In the case of osteolysis, a search should be made in particular for lung and renal cell carcinoma, and in the case of (partially) osteoplastic characteristics, particularly for prostate or breast carcinoma, but also gastric cancer.

#### Complementary diagnostics

- Histological confirmation! (DD plasmacytoma, Paget's disease, primary bone tumor, etc.)

#### Therapy

- Surgical resection with curative intention
- followed, if indicated, by radiotherapy.
- In case of unfavorable localization, primary definitive (not palliative!) radiotherapy.
- Depending on histology/histochemistry, immune checkpoint blockade or targeted therapy can be considered [45].

### **6.1.1.8 Solitary hepatic metastasis / oligometastasis in the liver**

#### Frequency and primary tumor

- Rare, usually multiple lesions present [35].
- Well-differentiated neuroendocrine tumors may have a favorable prognosis.

#### Therapy [36]

- Surgical resection or local ablative therapy.
- Palliative chemotherapy, if locoregional therapy is not feasible, see below, Chapter 6.1.3 (disseminated disease).

### **6.1.1.9 Solitary metastasis of malignant melanoma**

Is no longer considered as CUP syndrome.

#### Frequency and primary tumor

- Solitary lymph node metastases of malignant melanoma have a better prognosis with unknown primary tumor than with known primary tumor in several studies [46, 47], but not unequivocally [48].
- A recent comparative genomic analysis shows no significant differences between melanomas with unknown versus known primary [49].

#### Therapy

- As for malignant melanoma with known primary tumor.

### **6.1.1.10 Solitary skin or soft tissue metastasis other than melanoma, incl. Merkel cell carcinoma**

#### Frequency and primary tumor

- Rare; lung or breast carcinoma most common primary tumor [50].
- Merkel cell carcinoma has received special attention because of its specific and promising treatment options [51, 52]
- This can be clearly diagnosed histologically: neuroendocrine carcinoma with evidence of Merkel cell polyomavirus.

#### Therapy

- Surgical resection, followed by radiotherapy, if indicated.
- For Merkel cell tumor, immune checkpoint blockade with avelumab or pembrolizumab, if curative resection/radiotherapy is not possible.

## **6.1.2 Advanced stages**

### **6.1.2.1 Extragonadal germ cell tumors**

Are no longer considered as CUP syndrome.

- Can be reliably differentiated from other carcinomas by immunohistochemistry, see [Table 1](#)
- Consultation with the pathologist is essential!
- Attention is required in men, patients < 50 years, poorly differentiated carcinoma, retroperitoneal/mediastinal/pulmonary, rapid progression.

For details, see [Onkopedia Germ-cell Cancer](#) (German Version only).

### **6.1.2.2 Neuroendocrine tumors**

#### **6.1.2.2.1 Well-differentiated neuroendocrine tumors - NET Grades 1 and 2**

Do no longer count as CUP syndrome.

#### Frequency and primary tumor

- An unknown primary tumor is not uncommon in metastases of a well-differentiated neuroendocrine carcinoma, up to 20%. The spontaneous course is usually favorable, with frequent multiple liver metastases and much less frequent lung or skeletal metastases [53]. By means of specific immunohistochemistry and gene expression diagnostics, the type 'pancreatic NET' can almost always be distinguished from the type 'intestinal NET' and thus the primary tumor can often be localized [54, 55, 56].

#### Complementary diagnostics

- 68-gallium somatostatin receptor PET-CT; hormonal diagnosis for endocrine active NET, see ENETs guideline NET [57].

### Therapy

- As for metastatic differentiated neuroendocrine tumor, see ENETS guideline [58].
- Exploratory laparotomy often identifies the primary tumor; (only) in the case of completely resectable metastasis, it should be performed in an appropriate center [27].

#### **6.1.2.2 Undifferentiated neuroendocrine (small cell) carcinoma**

Do no longer count as CUP syndrome.

### Frequency and primary tumor

- Undifferentiated neuroendocrine carcinomas (NEC) can arise in a wide variety of organs.
- An unknown primary tumor is a rare special case.
- There is a relatively high chemotherapy sensitivity, but somewhat lower in extrapulmonary NEC than in small-cell lung cancer.
- Caution: Merkel cell carcinomas are also neuroendocrine carcinomas; it is mandatory that they be recognized (histologic evidence of Merkel cell polyomavirus).

### Therapy

- As for small-cell lung cancer, typically with platinum/etoposide-based chemotherapy, plus durvalumab or atezolizumab if PDL1 is expressed; plus radiotherapy if indicated, see [Onkopedia Small-Cell Lung Cancer](#).
- For Merkel cell carcinoma: immune checkpoint blockade.

#### **6.1.2.3 Women with peritoneal carcinomatosis due to adenocarcinoma**

Female serous high-grade carcinoma does no longer count as CUP syndrome.

### Criteria

- Female sex, peritoneal carcinomatosis, no other metastases ± malignant pleural/pericardial effusion ± retroperitoneal lymph node metastases.
- Patients with typical histology (serous papillary adenocarcinoma) should be classified as "primary peritoneal adenocarcinoma" rather than CUP syndrome.
- The prognosis is somewhat less favorable than for primary ovarian carcinoma [59].

### Therapy:

- As for ovarian cancer, with debulking surgery (if applicable), carboplatin/paclitaxel-based adjuvant or preoperative chemotherapy supplemented with bevacizumab.

In case of histology not compatible with ovarian cancer, especially adenocarcinoma compatible with pancreato-biliary or gastric profile ('upper GI') may present as a 'prognostically unfavorable CUP syndrome'. In some cases, the primary tumor is found in the appendix [60]. For therapy, see chapter 6.1.3 and Figure 8.

#### **6.1.2.4 Hormone-sensitive carcinoma**

##### **6.1.2.4.1 ER (estrogen receptor)-positive carcinoma**

###### Other criteria

- Breast cancer, endometrial carcinoma and ovarian carcinoma should be searched for thoroughly.
- Criteria for breast carcinoma: history of breast carcinoma (even decades ago), axillary, supraclavicular or mediastinal lymph node involvement, malignant pleural effusion, (mixed osteolytic-osteoplastic) skeletal metastasis, immunohistochemical: hormone receptor, HER2, mammaglobin A, GCDFP-15 and/or GATA3 expression, see also [Figure 4](#).

###### Therapy

- As in metastatic breast cancer, see [Onkopedia Female Breast Cancer](#) or [Male Breast cancer](#) (both Guidelines are in German only).

##### **6.1.2.4.2 AR (androgen receptor)-positive carcinoma**

- Prostate cancer is almost always AR-positive, but salivary gland tumors, triple-negative breast carcinomas, and others may also express AR.
- Criteria for prostate carcinoma include osteoplastic skeletal metastasis, elevated serum PSA, immunohistochemical proof of NKX3.1, PSMA, or PSA.

###### Therapy

- Androgen deprivation therapy as for metastatic prostate cancer, if appropriate, enzalutamide monotherapy if criteria for prostate cancer are not fulfilled.

##### **6.1.2.5 Colon-type adenocarcinoma (immunohistochemically CK7-, CK20+, CDX2+)**

###### Other criteria

- Liver metastases and/or peritoneal carcinomatosis.

###### Therapy [51]

- As for metastatic colorectal carcinoma, see [Onkopedia Colon Cancer](#) and [Onkopedia Rectal Cancer](#), respectively

##### **6.1.2.6 Renal-type carcinoma (clear-cell or papillary, immunohistochemical PAX8+, PAX2+, CD10+, Racemase+)**

###### Other criteria

- For differential diagnosis, refer to algorithm in [Figure 6](#). Pulmonary or skeletal metastases, retroperitoneal lymph node metastases may be present [20].

###### Therapy [51]

- As for metastatic renal cell carcinoma see [Onkopedia Renal Carcinoma](#).



### 6.1.3 Prognostically unfavorable manifestations

#### Criteria

- Disseminated metastasis either multiply in one organ (liver, lung, bone, brain, pleural or peritoneal carcinomatosis) or in different organ systems
- No affiliation to the defined groups, see chapter 5.4. prognosis and chapter 6. therapy).
- These 'unfavorable manifestations' account for 75-85% of CUP syndromes.

#### 6.1.3.1 Adenocarcinoma (ACUP) / undifferentiated carcinoma (UCUP) / squamous cell carcinoma (SqCUP) / malignant tumor NOS (not otherwise specified)

The therapeutic goal is palliative, i.e., prolongation of life / preservation or improvement of quality of life. The most important criterion for the choice of therapy is the characterization of the tumor biology.

In all patients with a possible therapeutic consequence, molecular testing by NGS (next generation sequencing) for possible driver mutations as well as for immunogenic tumor biology should be performed [20]. In any case, this includes diagnostics for microsatellite instability (MSI-H) or defects in mismatch repair enzymes (dMMR). These defects lead to a very high somatic mutation burden in a wide variety of primary tumors with good response to therapy with immune checkpoint inhibitors such as pembrolizumab. For this substance, a tumor-agnostic approval for first-line therapy is available by both the FDA and the EMA; thus, also for CUP syndrome.

Studies in CUP with regard to other predictors of a possible response to immune checkpoint blockade show a high TMB - tumor mutational burden - as a relevant criterion, the cutoff seems to be 10-12 mutations/megabase [14, 61].

In CUP, small phase II studies with pembrolizumab or with nivolumab as monotherapy [22, 23] show an objective remission rate (ORR) of approximately 20%, PFS of 4 months, and OS of 11-14 months. A phase II study with ipilimumab plus nivolumab as combination therapy shows an ORR of 16% in the overall group. This includes a 60% response with a small fraction of long-term survivors with high TMB (compared to only 7.7% at low TMB). In contrast, PDL1 status (pos. vs. neg.) has no prognostic significance in this study [61].

PDL1 expression (TPS and CPS) can provide an important tool for treatment with chemotherapy plus immune checkpoint blockade, especially in the presence of an immunogenic tumor (lung, gastroesophageal, cholangiocellular, urinary bladder, squamous cell carcinoma, and many others). A cut-off for TPS or CPS has not been determined in CUP. In 2nd- or further-line therapy, the option of immune checkpoint blockade in case of PDL1 expression has to be considered individually.

#### Therapy

- In case of MSI-H or dMMR: therapy with pembrolizumab
- In case of high tumor mutation burden (TMB-high, >12 mut./Megabase): PD1/PDL1 checkpoint inhibitor +/- CTLA4 inhibitor (note: off-label).
- In case of immunogenic tumor biology with PDL1 expression: consider PD1/PDL1 checkpoint inhibitor in the 2nd line of therapy (note: off-label).

Probably the most exciting current treatment approach is molecular targeted therapy based on genetic alterations of so-called 'druggable targets' on the tumor cells. In this process, molecular profiles of the tumor cells are created - optimally by means of NGS (next generation sequenc-

ing) - with the aim of identifying suitable targeted substances (e.g., tyrosine kinase inhibitors). The interpretation of the (often complex) findings takes place in a Molecular Tumor Board (MTB). Based on the recommendation of the MTB, an application for reimbursement of the proposed treatment must usually be written in Germany, which in turn is often approved by the Medical Service.

Genetic alterations are found in more than 85% of cases, while changes that are amenable to currently approved substances are found in about 30-35% [62, 63]. The subset of 'unfavorable CUP' could therefore become significantly smaller than before with consistent NGS testing. Alterations in KRAS, PIK3CA, FGFR ( $\geq 8\%$  each) are frequent, followed by BRAF and C-ERBB2; alterations in EGFR, MET, KRAS p.G12C, ROS1, NTRK and ALK are less frequent. Case reports and initial studies confirm the efficacy of this targeted approach [77]. The CUPISCO trial with 630 enrolled patients is investigating whether molecular characterization achieves better results than empirical chemotherapy in 'unfavorable CUP'; publication of first results in this regard is expected in the 2nd half of 2023 [21].

### Therapy

- As for known primary tumor with corresponding driver mutation.

If no indicators for molecular targeted therapy or immune checkpoint blockade are found, empirical chemotherapy is recommended. The choice of chemotherapy, e.g., combination therapy or monotherapy, should be based on age, comorbidity, LDH, functional status, and patient preferences, analogous to a geriatric assessment.

An overview of the therapy structure is given in [Figure 8](#).

### **6.1.3.2 Chemotherapy for adenocarcinoma (ACUP) / undifferentiated carcinoma (UCUP)**

#### First-line therapy

Currently, empirical chemotherapy continues to be the best-proven treatment. Data are available from several hundred patients treated in trials comparing different chemotherapy regimens. However, a randomized comparison to a best supportive care approach has never been studied in clinical trials. Treatment with carboplatin and paclitaxel has been best documented. Adding an EGFR antibody or a histone deacetylase inhibitor to chemotherapy without a biological marker as a selection criterion has shown no benefit [64, 65].

Empirical chemotherapy options supported by studies include:

- Carboplatin-paclitaxel-based chemotherapy [66, 67].
- Cisplatin - gemcitabine ('French regimen') (cave toxicity) [68]
- Gemcitabine - irinotecan (cave toxicity) [69, 70]

In many cases, treatment analogous to the presumed primary tumor is carried out in practice; but this approach is not evidence-based. It can be useful in individual cases, but it can also reduce the chances of therapeutic success: namely, if not the most therapy-sensitive, but rather the presumed most probable primary tumor is treated and no good treatment options exist for it. For example, the supposedly broadly effective combination capecitabine-oxaliplatin is not effective in first-line CUP even if criteria for a GI primary tumor are present, if the group of colon-typical CUP has been thoroughly excluded (see Chapter [6.1.2.5](#)), PFS was only 2.5 months, OS only 7.5 months in a well-documented prospective study [75].

In two randomized trials and a meta-analysis, aligning therapy with results by genetic profiling using a 92-gene test (CancerType ID) with the aim of better determining the possible primary tumor showed no advantage for 'personalized' therapy oriented to the presumed primary tumor over empirical chemotherapy [18, 71, 72]. Therefore, as a general rule, empirical chemotherapy is preferable due to the better evidence.

Details of the regimens can be found in the [German Treatment Protocols Appendix](#).

### Second-line therapy

There are no convincing studies for second-line therapy. The few available studies included small numbers of selected patients. If a driver mutation is detected, the corresponding agent, e.g., a TKI, should be given at the latest in the second line. In case of high tumor mutation burden (TMB-high) or pronounced PDL1 expression, immune checkpoint blockade is reasonable if not already given in the first line. In other cases, an alternative chemotherapy regimen from the first-line treatment options may be reasonable for patients in good general performance. In addition, in the second line, empiric therapy should always be considered based on the working diagnosis.

### **6.1.3.3 Chemo-/radiotherapy for squamous cell carcinoma (SqCUP)**

In squamous cell carcinomas, histology does not allow reliable conclusions with respect to the location of the primary tumor. HPV detection in metastases may point at primary gynecologic malignancies (cervical, vulvar/vaginal cancer), anal or penile cancer or oropharyngeal tumors. In the case of cervical lymph node metastases, a primary tumor in the oropharynx is likely, if HPV is detected, see Chapter 6.1.1.1. In numerous studies on CUP syndrome, squamous cell carcinomas are treated like adeno- and undifferentiated carcinomas, although a statement on the success of this therapy in the case of squamous cell histology is not possible due to its rarity.

### Therapy

- Combined radiochemotherapy, e.g., cisplatin/fluoropyrimidine or carboplatin AUC=2 / paclitaxel 50mg/m<sup>2</sup> weekly, plus immune checkpoint blockade if necessary for PDL1 expression.
- In second-line therapy, an immune checkpoint inhibitor is useful (if not already given in first-line), especially if there is evidence of immunogenic tumor biology.
- The administration of an EGFR antibody should be discussed on a case-by-case basis.

For the therapy structure, see [Figure 8](#).

## **6.3 Special situations**

### **6.3.1 Skeletal metastasis**

### Therapy

- Consistent analgesic medication, analgesic radiotherapy if needed.
- Consistent bisphosphonate or denosumab therapy.

A special setting is spinal metastasis with spinal cord compression: ***this is an oncological emergency!*** The prognosis is unfavorable, especially if visceral metastases are detected con-

currently and if the patient shows rapidly progressive paresis. Prompt surgery or radiotherapy can often prevent transverse syndrome [73].

## 8 Monitoring and follow-up

### 8.2 Follow-up

Evidence-based guidelines for follow-up in CUP syndrome are not available. Due to the multifaceted nature of the clinical signs and symptoms, detailed grades of recommendation are not useful. General recommendations are

- In case of curative therapy intention: structured follow-up according to specific cancer diagnosis.
- In case of palliative therapy intention: symptom-oriented follow-up.

## 9 References

1. Rassy E, Pavlidis N. The currently declining incidence of cancer of unknown primary. *Cancer Epidemiol.* 2019;61:139-141. DOI:10.1016/j.canep.2019.06.006.
2. Robert Koch Institute. Cause of death statistics in Germany 2020, ICD10 C80. <https://www.destatis.de/DE/Themen/Gesellschaft-Umwelt/Gesundheit/Todesursachen/Tabellen/sterbefaelle-krebs-insgesamt.html>
3. Yentz S, Bhave M, Cobain E, Baker L. Cancer of unknown primary. In: DeVita VTJ, Lawrence TS, Rosenberg SA, editors. *DeVita, Hellman, and Rosenberg's Cancer Principles & Practice of Oncology.* 12 ed. Philadelphia, Baltimore, New York: Walters Kluwer Health; 2023. pp. 1856-62. ISBN-13:9781975184742.
4. Moiso E, Farahani A, Marble HD, et al. Developmental deconvolution for classification of cancer origin. *Cancer Discov.* 2022;12:2566-2585. DOI:10.1158/2159-8290.CD-21-1443
5. Verginelli F, Pisacane A, Gambardella G, et al. Cancer of unknown primary stem-like cells model multi-organ metastasis and unveil liability to MEK inhibition. *Nat Commun.* 2021;12:2498. DOI:10.1038/s41467-021-22643-w
6. Lee G, Hall RR, 3rd, Ahmed AU. Cancer stem cells: cellular plasticity, niche, and its clinical relevance. *J Stem Cell Res Ther.* 2016;6:363. DOI:10.4172/2157-7633.1000363.
7. Hemminki K, Försti A, Sundquist K, Li X. Cancer of unknown primary is associated with diabetes. *Eur J Cancer Prev.* 2016;25:246-251. DOI:10.1097/CEJ.000000000000165.
8. Kaaks R, Sookthai D, Hemminki K, et al. Risk factors for cancers of unknown primary site: Results from the prospective EPIC cohort. *Int J Cancer.* 2014;135:2475-2481. DOI:10.1002/ijc.28874
9. Selves J, Long-Mira E, Mathieu MC, Rochaix P, Ilié M. Immunohistochemistry for diagnosis of metastatic carcinomas of unknown primary site. *Cancers (Basel).* 2018;10:108. DOI:10.3390/cancers10040108
10. Losa F, Iglesias L, Pane M, et al. 2018 consensus statement by the Spanish Society of Pathology and the Spanish Society of Medical Oncology on the diagnosis and treatment of cancer of unknown primary. *Clin Transl Oncol.* 2018;20:1361-1372. DOI:10.1007/s12094-018-1899-z
11. Kandalaft PL, Gown AM. Practical applications in immunohistochemistry: carcinomas of unknown primary site. *Arch Pathol Lab Med.* 2016;140:508-523. DOI:10.5858/arpa.2015-0173-CP.

12. Posner A, Sivakumaran T, Pattison A, et al. Immune and genomic biomarkers of immunotherapy response in cancer of unknown primary. *J Immunother Cancer*. 2023;11:e005809. DOI:10.1136/jitc-2022-005809
13. Bochtler T, Wohlfromm T, Hielscher T, et al. Prognostic impact of copy number alterations and tumor mutational burden in carcinoma of unknown primary. *Genes Chromosomes Cancer*. 2022;61:551-560. DOI:10.1002/gcc.23047
14. Rassy E, Boussios S, Pavlidis N. Genomic correlates of response and resistance to immune checkpoint inhibitors in carcinomas of unknown primary. *Eur J Clin Invest*. 2021;51:e13583. DOI:10.1111/eci.13583
15. Laprovitera N, Riefolo M, Porcellini E, et al. MicroRNA expression profiling with a droplet digital PCR assay enables molecular diagnosis and prognosis of cancers of unknown primary. *Mol Oncol*. 2021;15:2732-2751. DOI:10.1002/1878-0261.13026.
16. Santos MTD, Souza BF, Carcano FM, et al. An integrated tool for determining the primary origin site of metastatic tumors. *J Clin Pathol*. 2018;71:584-593. DOI:10.1136/jclin-path-2017-204887.
17. Moran S, Martinez-Cardus A, Sayols S, et al. Epigenetic profiling to classify cancer of unknown primary: a multicentre, retrospective analysis. *Lancet Oncol*. 2016;17:1386-1395. DOI:10.1016/S1470-2045(16)30297-2.
18. Rassy E, Bakouny Z, Choueiri TK, et al. The role of site-specific therapy for cancers of unknown of primary: A meta-analysis. *Eur J Cancer*. 2020;127:118-122. DOI:10.1016/j.ejca.2019.12.016
19. van der Strate I, Kazemzadeh F, Nagtegaal ID, et al. International consensus on the initial diagnostic workup of cancer of unknown primary. *Crit Rev Oncol Hematol*. 2023;181:103868. DOI:10.1016/j.critrevonc.2022.103868.
20. Krämer A, Bochtler T, Pauli C, et al. Cancer of unknown primary: ESMO Clinical Practice Guideline for diagnosis, treatment and follow-up. *Ann Oncol*. 2023;34:228-246. DOI:10.1016/j.annonc.2022.11.013.
21. Kramer A, Losa F, Gay C, al. Comprehensive profiling and molecularly guided therapy (MGT) for carcinomas of unknown primary (CUP): CUPISCO: A phase II, randomised, multi-centre study comparing targeted therapy or immunotherapy with standard platinum-based chemotherapy. *Ann Oncol*. 2018;29(suppl 8):445TiP. DOI:10.1093/annonc/mdy279.432
22. Tanizaki J, Yonemori K, Akiyoshi K, et al. Open-label phase II study of the efficacy of nivolumab for cancer of unknown primary. *Ann Oncol*. 2022;33:216-226. DOI:10.1016/j.annonc.2021.11.009.
23. Raghav KP, Stephen B, Karp DD et al. Efficacy of pembrolizumab in patients with advanced cancer of unknown primary (CUP): a phase 2 non-randomized clinical trial. *J Immunother Cancer*. 2022;10:e004822. DOI:10.1136/jitc-2022-004822
24. Schroeder L, Pring M, Ingarfield K, et al. HPV driven squamous cell head and neck cancer of unknown primary is likely to be HPV driven squamous cell oropharyngeal cancer. *Oral Oncol*. 2020;107:104721. DOI:10.1016/j.oraloncology.2020.104721.
25. Woo S, Becker AS, Do RKG, Schöder H, Hricak H, Alberto Vargas H. Impact of (18)F-fluorodeoxyglucose positron emission tomography on management of cancer of unknown primary: systematic review and meta-analysis. *Eur J Cancer*. 2021;159:60-77. DOI:10.1016/j.ejca.2021.09.031.
26. Mackenzie K, Watson M, Jankowska P, Bhide S, Simo R. Investigation and management of the unknown primary with metastatic neck disease: United Kingdom National Multidisciplinary Guidelines. *J Laryngol Otol*. 2016;130(S2):S170-S175. DOI:10.1017/S0022215116000591.

27. Keck KJ, Maxwell JE, Menda Y, et al. Identification of primary tumors in patients presenting with metastatic gastroenteropancreatic neuroendocrine tumors. *Surgery*. 2017;161:272-279. DOI:10.1016/j.surg.2016.05.055
28. Pauli C, Bochtler T, Mileschkin L, et al. A challenging task: identifying patients with cancer of unknown primary (CUP) according to ESMO Guidelines: The CUPISCO trial experience. *Oncologist*. 2021;26:e769-e779. DOI:10.1002/onco.13744
29. Ferte C, Penel N, Bonnetterre J, Adenis A. Individual life expectancy estimation using validated prognostic scores for patients with cancer of unknown primary. *Oncology*. 2010;78:87-93. DOI:10.1159/000306137
30. Maghami E, Ismaila N, Alvarez A, et al. Diagnosis and management of squamous cell carcinoma of unknown primary in the head and neck: ASCO Guideline. *J Clin Oncol*. 2020;38:2570-2596. DOI:10.1200/JCO.20.00275.
31. Cheraghlou S, Torabi SJ, Husain ZA, et al. HPV status in unknown primary head and neck cancer: prognosis and treatment outcomes. *Laryngoscope*. 2019;129:684-691. DOI:10.1002/lary.27475
32. Müller von der Grün J, Tahtali A, Ghanaati S, Rödel C, Balermipas P. Diagnostic and treatment modalities for patients with cervical lymph node metastases of unknown primary site - current status and challenges. *Radiat Oncol*. 2017;12:82. DOI:10.1186/s13014-017-0817-9.
33. Arosio AD, Pignataro L, Gaini RM, Garavello W. Neck lymph node metastases from unknown primary. *Cancer Treat Rev*. 2017 Feb;53:1-9. DOI:10.1016/j.ctrv.2016.11.014.
34. Müller von der Grün J, Bon D, Rödel C, Balermipas P. Patterns of care analysis for head & neck cancer of unknown primary site: a survey inside the German society of radiation oncology (DEGRO). *Strahlenther Onkol*. 2018;194:750-758. DOI:10.1007/s00066-018-1308-0.
35. Brenet E, Philouze P, Schiffler C, et al. Influence of postoperative radiotherapy target volumes in unilateral head and neck carcinoma of unknown primary: A multicentric study using propensity score. *Radiother Oncol*. 2021;160:1-8. DOI:10.1016/j.radonc.2021.04.002.
36. Straetmans JMJA, Stuut M, Wagemakers S, et al. Tumor control of cervical lymph node metastases of unknown primary origin: the impact of the radiotherapy target volume. *Eur Arch Otorhinolaryngol*. 2020;277:1753-1761. DOI:10.1007/s00405-020-05867-2.
37. Tiong A, Rischin D, Young RJ, et al. Unilateral radiotherapy treatment for p16/human papillomavirus-positive squamous cell carcinoma of unknown primary in the head and neck. *Laryngoscope*. 2018;128:2076-2083. DOI:10.1002/lary.27131
38. Cabrera Rodriguez J, Cacicedo J, Giral J, et al. GEORCC recommendations on target volumes in radiotherapy for head neck cancer of unknown primary. *Crit Rev Oncol Hematol*. 2018;130:51-59. DOI:10.1016/j.critrevonc.2018.07.006.
39. Franzen A, Günzel T, Buchali A, Coordes A. Etiologic and differential diagnostic significance of tumor location in the supraclavicular fossa. *Laryngoscope*. 2018;128:646-650. DOI:10.1002/lary.26775
40. Kim H, Park W, Kim SS, et al. Prognosis of patients with axillary lymph node metastases from occult breast cancer: analysis of multicenter data. *Radiat Oncol J*. 2021;39:107-112. DOI:10.3857/roj.2021.00241.
41. Pentheroudakis G, Lazaridis G, Pavlidis N. Axillary nodal metastases from carcinoma of unknown primary (CUPAx): a systematic review of published evidence. *Breast Cancer Res Treat*. 2010;119:1-11. DOI:10.1007/s10549-009-0554-3.

42. Simões Padilla C, Ho VKY, van der Strate IH, et al. Prognostic factors among patients with brain metastases from cancer of unknown primary site. *J Neurooncol.* 2022;159:647-655. DOI:10.1007/s11060-022-04106-4.
43. Bakow BR, Elco CP, LeGolvan M, Dizon D, Ollila TA. Molecular profiles of brain and pulmonary metastatic disease in cancer of unknown primary. *Oncologist.* 2020;25:555-559. DOI:10.1634/theoncologist.2019-0798
44. Rassy E, Zanaty M, Azoury F, Pavlidis N. Advances in the management of brain metastases from cancer of unknown primary. *Future Oncol.* 2019;15:2759-2768. DOI:10.2217/fon-2019-0108.
45. Raghav K, Overman M, Poage GM, Soifer HS, Schnabel CA, Varadhachary GR. Defining a distinct immunotherapy eligible subset of patients with cancer of unknown primary using gene expression profiling with the 92-gene assay. *Oncologist.* 2020;25:e1807-e1811. DOI:10.1634/theoncologist.2020-0234
46. Gullestad HP, Ryder T, Goscinski M. Survival after lymphadenectomy of nodal metastases from melanoma of unknown primary site. *J Plast Surg Hand Surg.* 2023;57:109-114. DOI:10.1080/2000656X.2021.2010739.
47. Bae JM, Choi YY, Kim DS, et al. Metastatic melanomas of unknown primary show better prognosis than those of known primary: a systematic review and meta-analysis of observational studies. *J Am Acad Dermatol.* 2015;72:59-70. DOI:10.1016/j.jaad.2014.09.029
48. Boussios S, Rassy E, Samartzis E, et al. Melanoma of unknown primary: New perspectives for an old story. *Crit Rev Oncol Hematol.* 2021;158:103208. DOI:10.1016/j.critrevonc.2020.103208.
49. Rassy E, Boussios S, Chebly A, Farra C, Kattan J, Pavlidis N. Comparative genomic characterization of melanoma of known and unknown primary. *Clin Transl Oncol.* 2021;23:2302-2308. DOI:10.1007/s12094-021-02629-2.
50. Handa U, Kundu R, Dimri K. Cutaneous metastasis: a study of 138 cases diagnosed by fine-needle aspiration cytology. *Acta Cytol.* 2017;61:47-54. DOI:10.1159/000453252.
51. Broida SE, Chen XT, Baum CL, et al. Merkel cell carcinoma of unknown primary: clinical presentation and outcomes. *J Surg Oncol.* 2022;126:1080-1086. DOI:10.1002/jso.27010.
52. Kotteas EA, Pavlidis N. Neuroendocrine Merkel cell nodal carcinoma of unknown primary site: management and outcomes of a rare entity. *Crit Rev Oncol Hematol.* 2015;94:116-121. DOI:10.1016/j.critrevonc.2014.12.005.
53. Stoyianni A, Pentheroudakis G, Pavlidis N. Neuroendocrine carcinoma of unknown primary: a systematic review of the literature and a comparative study with other neuroendocrine tumors. *Cancer Treat Rev.* 2011;37:358-365. DOI:10.1016/j.ctrv.2011.03.002.
54. Juhlin CC, Zedenius J, Höög A. Metastatic neuroendocrine neoplasms of unknown primary: clues from pathology workup. *Cancers (Basel).* 2022;14:2210. DOI:10.3390/cancers14092210
55. de Mestier L, Nicolle R, Poté N, et al. Molecular deciphering of primary liver neuroendocrine neoplasms confirms their distinct existence with foregut-like profile. *J Pathol.* 2022;258:58-68. DOI:10.1002/path.5977.
56. Yang Z, Klimstra DS, Hruban RH, Tang LH. Immunohistochemical characterization of the origins of metastatic well-differentiated neuroendocrine tumors to the Liver. *Am J Surg Pathol.* 2017;41:915-922. DOI:10.1097/PAS.0000000000000876.
57. Sundin A, Arnold R, Baudin E, Cwikla JB, Eriksson B, Fanti S, et al. ENETS consensus guidelines for the standards of care in neuroendocrine tumors: radiological, nuclear medicine & hybrid imaging. *Neuroendocrinology.* 2017;105:212-244. DOI:10.1159/000471879

58. Pavel M, de Herder WW. ENETS consensus guidelines for the standard of care in neuroendocrine tumors. *Neuroendocrinology*. 2017;105:193-195. DOI:10.1159/000457957
59. Dahm-Kahler P, Borgfeldt C, Holmberg E, Staf C, Falconer H, Bjurberg M, et al. Population-based study of survival for women with serous cancer of the ovary, fallopian tube, peritoneum or undesignated origin - on behalf of the Swedish gynecological cancer group (SweGCG). *Gynecol Oncol*. 2017;144:167-173. DOI:10.1016/j.ygyno.2016.10.039
60. Sugarbaker PH. Peritoneal carcinomatosis of unknown primary site, a study of 25 patients over 30 years. *Eur J Surg Oncol*. 2020;46:1908-1911. DOI:10.1016/j.ejso.2020.03.217.
61. Pouyiourou M, Kraft B, Wohlfromm T, et al. Combined ipilimumab and nivolumab in previously treated patients with cancer of unknown primary: Results of the CheCUP trial. *Ann Oncol*. 2022;33(Suppl7):S881. DOI:10.1016/j.annonc.2022.07.864
62. Westphalen CB, Karapetyan A, Beringer A, et al. Baseline mutational profiles of patients (pts) with carcinoma-of-unknown-primary-origin (CUP) enrolled onto CUPISCO. *Ann Oncol*. 2021;32(Suppl5):S1227-S1228. DOI:10.1016/j.annonc.2021.08.258
63. Ross JS, Sokol ES, Moch H, et al. Comprehensive genomic profiling of carcinoma of unknown primary origin: retrospective molecular classification considering the CUPISCO study design. *Oncologist*. 2021;26:e394-e402. DOI:10.1002/onco.13597
64. Folprecht G, Trautmann K, Stein A, et al. Adding cetuximab to paclitaxel and carboplatin for first-line treatment of carcinoma of unknown primary (CUP): results of the phase 2 AIO trial PACET-CUP. *Br J Cancer*. 2021;124:721-727. DOI:10.1038/s41416-020-01141-8
65. Hainsworth JD, Daugaard G, Lesimple T, et al. Paclitaxel/carboplatin with or without belinostat as empiric first-line treatment for patients with carcinoma of unknown primary site: A randomized, phase 2 trial. *Cancer*. 2015;121:1654-1661. DOI:10.1002/cncr.29229
66. Lee J, Hahn S, Kim DW, et al. Evaluation of survival benefits by platinum and taxanes for an unfavourable subset of carcinoma of unknown primary: a systematic review and meta-analysis. *Br J Cancer*. 2013;108:39-48. DOI:10.1038/bjc.2012.516
67. Hübner G, Link H, Köhne CH, et al. Paclitaxel and carboplatin vs gemcitabine and vinorelbine in patients with adeno- or undifferentiated carcinoma of unknown primary: a randomised prospective phase II trial. *Br J Cancer*. 2009;100:44-49. DOI:10.1038/sj.bjc.6604818
68. Gross-Goupil M, Fourcade A, Blot E, et al. Cisplatin alone or combined with gemcitabine in carcinomas of unknown primary: results of the randomised GEFCAPI 02 trial. *Eur J Cancer*. 2012;48:721-727. DOI:10.1016/j.ejca.2012.01.011
69. Holtan SG, Steen PD, Foster NR, et al. Gemcitabine and irinotecan as first-line therapy for carcinoma of unknown primary: results of a multicenter phase II trial. *PLoS One*. 2012;7:e39285. DOI:10.1371/journal.pone.0039285
70. Hainsworth JD, Spigel DR, Clark BL, et al. Paclitaxel/carboplatin/etoposide versus gemcitabine/irinotecan in the first-line treatment of patients with carcinoma of unknown primary site: a randomized, phase III Sarah Cannon Oncology Research Consortium trial. *Cancer J*. 2010;16:70-75. DOI:10.1097/PPO.0b013e3181c6aa89
71. Hayashi H, Kurata T, Takiguchi Y, et al. Randomized phase II trial comparing site-specific treatment based on gene expression profiling with carboplatin and paclitaxel for patients with cancer of unknown primary site. *J Clin Oncol*. 2019;37:570-579. DOI:10.1200/JCO.18.00771
72. Fizazi K, Maillard E, Penel N, et al. A phase 3 trial of empiric chemotherapy with cisplatin and gemcitabine or systemic treatment tailored by molecular gene expression analysis in patients with a carcinoma of unknown primary site (GEFCAPI 04). *Ann Oncol*. 2019;30(Suppl. 5):v851-v943. DOI:10.1093/annonc/mdz394



73. Rades D, Conde-Moreno AJ, Garcia R, Veninga T, Schild SE. A tool to estimate survival of elderly patients presenting with metastatic epidural spinal cord compression (MESCC) from cancer of unknown primary. *Anticancer Res.* 2015;35:6219-6222. [PMID:26504054](#).
74. Kraywinkel K, Zeißig S. Epidemiology of the CUP syndrome in Germany. *Onkologe.* 2017;23:966–973. [DOI:10.1007/s00761-017-0301-z](#)
75. Schuette K, Folprecht G, Kretschmar A, et al. Phase II trial of capecitabine and oxaliplatin in patients with adeno- and undifferentiated carcinoma of unknown primary. *Oncology.* 2009;32:162-166. [DOI:10.1159/000201125](#)
76. Kolling S, Ventre F, Geuna E, et al. "Metastatic Cancer of Unknown Primary" or "Primary Metastatic Cancer"? *Front Oncol* 2020;9:1546. [DOI:10.3389/fonc.2019.01546](#)
77. Möhrmann L, Werner M, Oleś M, et al. Comprehensive genomic and epigenomic analysis in cancer of unknown primary guides molecularly-informed therapies despite heterogeneity. *Nat Commun.* 2022;13:4485. [DOI:10.1038/s41467-022-31866-4](#)
78. Bochtler T, Endris V, Leichsenring J, et al. Comparative genetic profiling aids diagnosis and clinical decision making in challenging cases of CUP syndrome. *Int J Cancer.* 2019;145:2963-2973. [DOI:10.1002/ijc.32316](#)

## 16 Authors' Affiliations

### **Dr. med. Gerdt Hübner**

Ameos Kliniken Ostholstein  
Hospitalstr. 22  
23701 Eutin  
[gerdt.huebner@ameos.de](mailto:gerdt.huebner@ameos.de)

### **PD Dr. med. Tilmann Bochtler**

Nationales Centrum für Tumorerkrankungen (NCT), Universitätsklinikum Heidelberg  
Klinische Kooperationseinheit Molekulare Hämatologie/Onkologie,  
Med. Klinik V und Deutsches Krebsforschungszentrum (DKFZ), Heidelberg  
Im Neuenheimer Feld 460  
69120 Heidelberg  
[Tilmann.Bochtler@med.uni-heidelberg.de](mailto:Tilmann.Bochtler@med.uni-heidelberg.de)

### **Prof. Dr. med. Markus Borner**

ONCOCARE am Engeriedspital  
Riedweg 15  
CH-3012 Bern  
[markus.borner@hin.ch](mailto:markus.borner@hin.ch)

### **Prof. Dr. Herbert Stöger**

Landeskrankenhaus-Universitätsklinikum  
Graz  
Klinische Abteilung für Onkologie  
Auenbrugger Platz 15  
A-8036 Graz  
[herbert.stoeger@medunigraz.at](mailto:herbert.stoeger@medunigraz.at)

**Prof. Dr. Kai Neben**

Klinikum Mittelbaden  
Baden-Baden Balg  
Medizinische Klinik 2  
Balgerstr. 50  
76532 Baden-Baden  
[k.neben@klinikum-mittelbaden.de](mailto:k.neben@klinikum-mittelbaden.de)

**Prof. Dr. med. Thomas Ernst**

Universitätsklinikum Jena  
Klinik für Innere Medizin II  
Am Klinikum 1  
07747 Jena  
[thomas.ernst@med.uni-jena.de](mailto:thomas.ernst@med.uni-jena.de)

**Dr. med. Klaus Kraywinkel**

Zentrum für Krebsregisterdaten  
Robert Koch-Institut  
General-Pape-Straße 62-66  
12101 Berlin  
[k.kraywinkel@rki.de](mailto:k.kraywinkel@rki.de)

**Dr. med. Lena Weiss**

LMU Klinikum - Campus Großhadern  
Medizinische Klinik und Poliklinik III  
Marchioninistr. 15  
80336 München  
[lena.weiss@med.uni-muenchen.de](mailto:lena.weiss@med.uni-muenchen.de)

## **17 Disclosure of Potential Conflicts of Interest**

according to the [rules of DGHO, OeGHO, SGH+SSH, SGMO](#)

Author	Employer <sup>1</sup>	Consulting / Expert opinion <sup>2</sup>	Shares / Funds <sup>3</sup>	Patent / Copyright / License <sup>4</sup>	Fees <sup>5</sup>	Funding of scientific research <sup>6</sup>	Other financial relations <sup>7</sup>	Personal relationship with authorized representatives <sup>8</sup>
Bochtler, Tilmann	Nationales Centrum für Tumorerkrankungen (NCT) Heidelberg Universitätsklinikum Heidelberg Im Neuenheimer Feld 460 69120 Heidelberg Klinische Kooperationsseinheit Molekulare Hämatologie / Onkologie, Deutsches Krebsforschungszentrum Heidelberg (DKFZ) und Medizinische Klinik V, Im Neuenheimer Feld 280 69120 Heidelberg	No	No	No	Yes Arbeit als Studienonkologe für die CUPISCO Studie, die von Roche gesponsort wird. Im Rahmen dieser Tätigkeit Vergütung der Arbeit als Studienonkologe / Vorträge an den Arbeitgeber (keine persönlichen Honorare)	No	Yes Arbeit als Studienonkologe für die CUPISCO Studie, die von Roche gesponsort wird. Im Rahmen dieser Tätigkeit Erstattung von studienbezogenen Reisen.	No
Borner, Markus	Selbständig	No	No	No	No	No	No	No
Ernst, Thomas	Universitätsklinikum Jena	No	No	No	No	No	No	No
Hübner, Gerdt	1. Selbst (eigene Praxis) 2. Ameos Klinika Ostholstein (Teilzeit), Hospitalstr. 22, 23701 Eutin	Yes Roche	No	No	Yes Roche	No	No	No
Kraywinkel, Klaus	Robert Koch-Institut, Berlin	No	No	No	No	No	No	No
Neben, Kai	Klinikum Mittelbaden Abteilung für Hämatologie, Onkologie und Palliativmedizin Balgerstrasse 50 76532 Baden-Baden	Yes Janssen, BMS, MSD, Takeda, Sanofi, Miltenyi, Pfizer, Roche, AstraZeneca, Novartis	No	No	No	No	No	No
Stöger, Herbert	seit 10/2021 an Medizinischer Universität Graz im Ruhestand; laufende internistische-onkologische Ordination;	No	No	No	No	No	No	No
Weiss, Lena	Klinikum der Universität München	No	No	No	Yes Servier, Roche	Yes Illumina	Yes AMGEN	No

Legend:

<sup>1</sup> - Current employer, relevant previous employers in the last 3 years (institution/location).

<sup>2</sup> - Activity as a consultant or expert or paid participation in a scientific advisory board of a company in the health care industry (e.g., pharmaceutical industry, medical device industry), a commercially oriented contract research organization, or an insurance company.

<sup>3</sup> - Ownership of business shares, stocks, funds with participation of companies of the health care industry.

<sup>4</sup> - Relates to drugs and medical devices.

<sup>5</sup> - Honoraria for lecturing and training activities or paid authors or co-authorships on behalf of a company in the health care industry, a commercially oriented contracting institute or an insurance company.

<sup>6</sup> - Financial support (third-party funds) for research projects or direct financing of employees of the institution by a company in the health care industry, a commercially oriented contract institute or an insurance company.

<sup>7</sup> - Other financial relationships, e.g., gifts, travel reimbursements, or other payments in excess of 100 euros outside of research projects, if paid by an entity that has an investment in, license to, or other commercial interest in the subject matter of the investigation.

<sup>8</sup> - Personal relationship with an authorized representative(s) of a healthcare company.